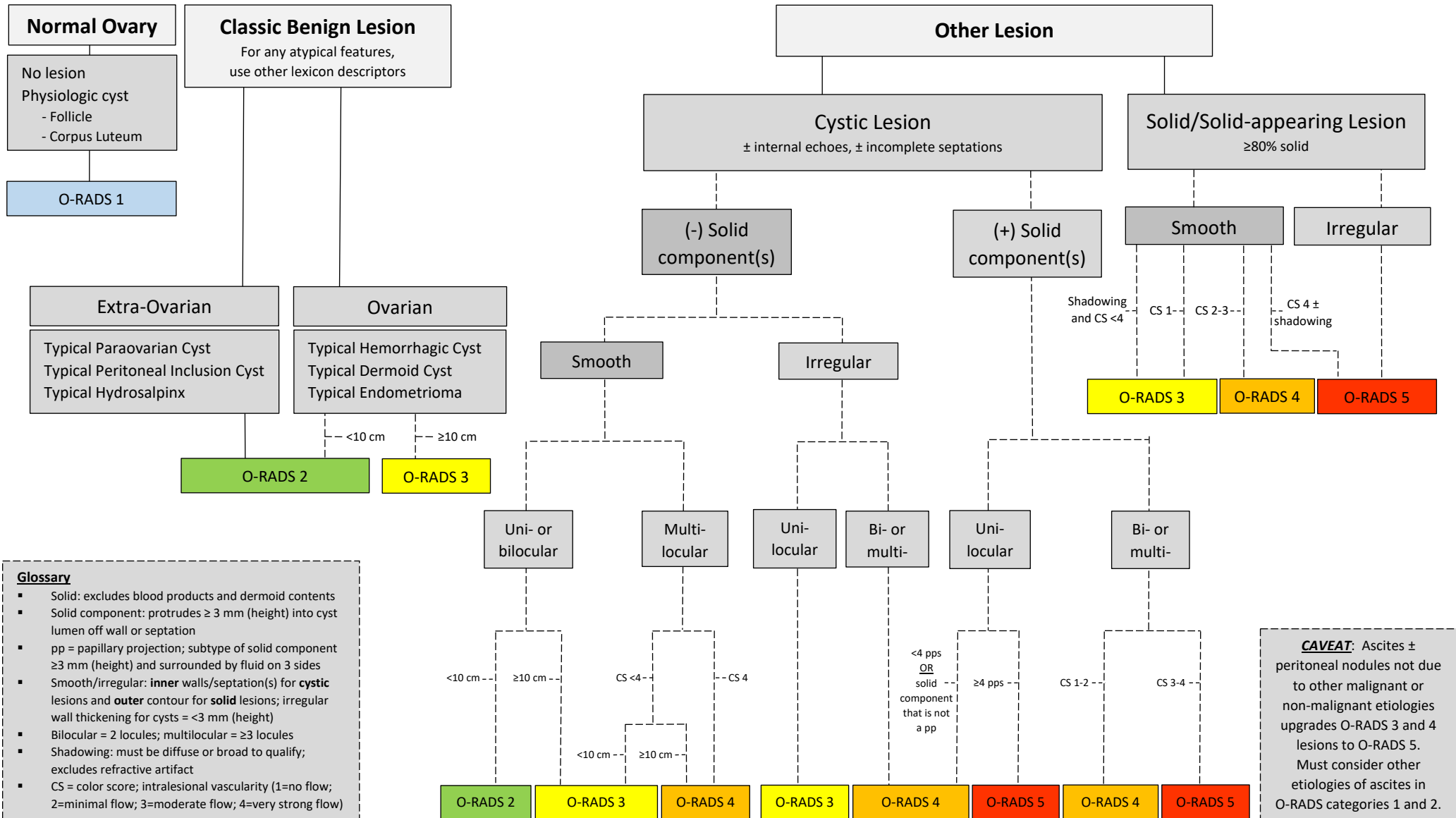


# O-RADS™ Ultrasound v2022 Assessment Categories



**Glossary**

- Solid: excludes blood products and dermoid contents
- Solid component: protrudes ≥ 3 mm (height) into cyst lumen off wall or septation
- pp = papillary projection; subtype of solid component ≥3 mm (height) and surrounded by fluid on 3 sides
- Smooth/irregular: **inner** walls/septation(s) for **cystic** lesions and **outer** contour for **solid** lesions; irregular wall thickening for cysts = <3 mm (height)
- Bilocular = 2 locules; multilocular = ≥3 locules
- Shadowing: must be diffuse or broad to qualify; excludes refractive artifact
- CS = color score; intralesional vascularity (1=no flow; 2=minimal flow; 3=moderate flow; 4=very strong flow)

**CAVEAT:** Ascites ± peritoneal nodules not due to other malignant or non-malignant etiologies upgrades O-RADS 3 and 4 lesions to O-RADS 5. Must consider other etiologies of ascites in O-RADS categories 1 and 2.