

III. REPORTING SYSTEM

MAGNETIC RESONANCE
IMAGING

A. REPORT ORGANIZATION

The reporting system should be concise and organized. Any pertinent clinical history that may affect scan interpretation, as well as any MRI acquisition techniques (including postprocessing information) that may affect the scan interpretation, should be described. The breast MRI report should first describe the amount of fibroglandular tissue and the background parenchymal enhancement (BPE). Abnormal enhancement (unique and separate from the BPE) is described based on morphology, distribution, and kinetics. Results from any physiologic or parametric imaging should be described. An assessment is rendered that includes the degree of concern and any recommendation(s). Benign findings need not be reported, especially if the interpreting physician is concerned that the referring clinician or patient might infer anything other than absolute confidence in benignity.

Table 2. Report Organization

Report Structure
1. Indication for examination
2. MRI technique
3. Succinct description of overall breast composition
4. Clear description of any important findings
5. Comparison to previous examination(s)
6. Assessment
7. Management

1. INDICATION FOR EXAMINATION

Provide a brief description of the indication for examination. For example, this may be high-risk screening, follow-up of a probably benign lesion, follow-up of cancer treated with neoadjuvant chemotherapy, or evaluation of the newly diagnosed cancer patient.

As background parenchymal enhancement can be affected by cyclical hormonal changes, it may be helpful to include menstrual history. If the patient is pre-menopausal, the week of the menstrual cycle may be important information to aid in interpretation. Current therapy (neoadjuvant, adjuvant, hormonal, or radiation therapy) for breast cancer treatment in the pre- or postsurgical setting may be important information and may inform exam interpretation.

The indication for examination should contain a concise description of the patient's clinical history, including:

- a. Reason for performing the exam (e.g., screening, staging, problem solving)
- b. Clinical abnormalities, including size, location, and duration
 - i. Palpable finding
 - ii. Nipple discharge
 - iii. Other pertinent clinical findings or history

- c. Previous biopsies
 - i. Biopsy type
 - ii. Biopsy location
 - iii. Benign or malignant pathology (cytology or histology)
- d. Hormonal status if applicable
 - i. Pre- or post-menopausal
 - ii. Menstrual cycle phase (second week or other) or last menstrual period
 - iii. Peripartum
 - iv. Exogenous hormone therapy, tamoxifen, aromatase inhibitors, or other hormones or medications/herbs/vitamins that might influence MRI

2. MRI TECHNIQUE

Give a detailed description of the technical factors of how the MRI examination was obtained. At a minimum, a bright-fluid sequence of both breasts should be obtained. Pre- and post-gadolinium T1-weighted images should be obtained, preferably with fat suppression, simultaneously of both breasts. Subtraction imaging may be desired as well as other as processing techniques and parametric analysis. Elements of this description routinely include:

- a. Right, left, or both breasts
- b. Location of markers and their significance (scar, nipple, palpable lesion, etc.)
- c. Weighting
 - i. T1 weighted
 - ii. T2 weighted
 - iii. Fat saturation
 - iv. Scan orientation and plane
 - v. Other pertinent pulse sequence features
- d. Contrast dose
 - i. Name of contrast agent
 - ii. Dosage (mmol/kg) and volume (in cc)
 - iii. Injection type: bolus or infusion
 - iv. Timing (relationship of bolus injection to scan start time and scan length)
 - v. If multiple scans: number of postcontrast scans and acquisition techniques of each (how fast, how many slices, and slice thickness)
- e. Postprocessing techniques as applicable
 - i. MPR/MIP
 - ii. Time/signal intensity curves
 - iii. Subtraction
 - iv. Other techniques

3. SUCCINCT DESCRIPTION OF OVERALL BREAST COMPOSITION

This should include an overall description of the breast composition, including:

- a. The amount of FGT that is present

Table 3. Breast Tissue — Fibroglandular Tissue (FGT)

Amount of Fibroglandular Tissue
a. Almost entirely fat
b. Scattered fibroglandular tissue
c. Heterogeneous fibroglandular tissue
d. Extreme fibroglandular tissue

The four categories of breast composition ([Table 3](#)) are defined by the visually estimated content of FGT within the breasts. If the breasts are not of apparently equal amounts of FGT the breast with the most FGT should be used to categorize breast composition. Although there may be considerable variation in visually estimating breast composition, categorizing based on percentages (and specifically into quartiles) is not recommended. We recognize that quantification of breast FGT volume on MRI may be feasible in the future, but we await publication of robust data before endorsing percentage recommendations. We urge the use of BI-RADS® terminology instead of numbers to classify breast FGT in order to eliminate any possible confusion with the BI-RADS® assessment categories, which are numbered.

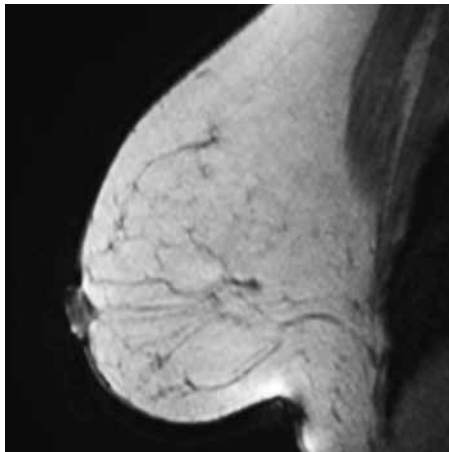


Figure 262 – Almost entirely fat.

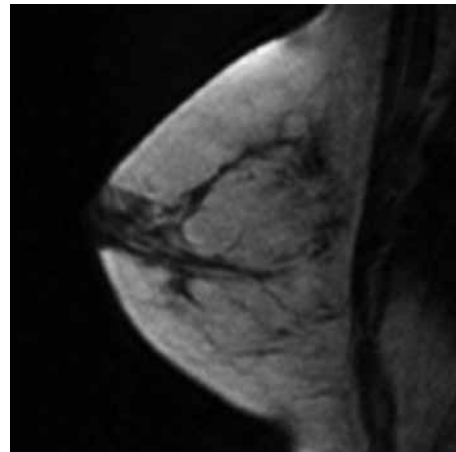


Figure 263 – Scattered fibroglandular tissue.

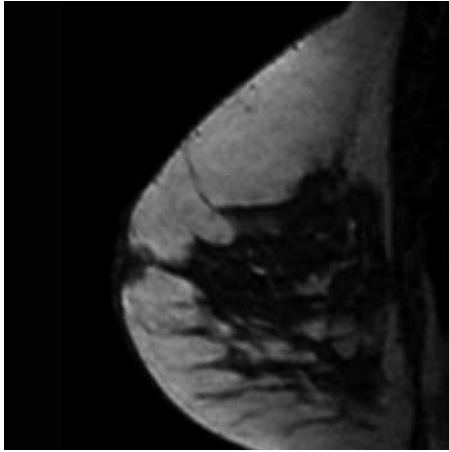


Figure 264 – Heterogeneous fibroglandular tissue.

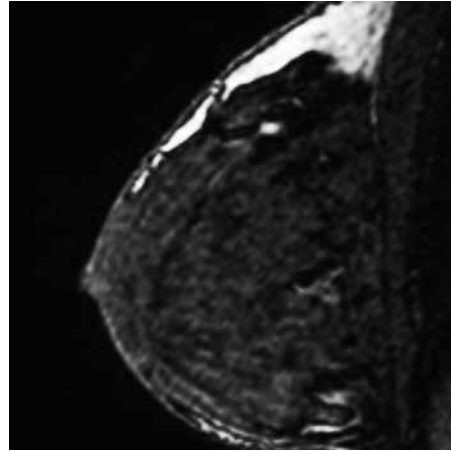


Figure 265 – Extreme fibroglandular tissue.

- b. The amount of background parenchymal enhancement in the image

Table 4. Breast Tissue — Background Parenchymal Enhancement (BPE)

Background Parenchymal Enhancement
a. Minimal
b. Mild
c. Moderate
d. Marked

The four categories of BPE ([Table 4](#)) are defined by the visually estimated enhancement of the FGT of the breast(s). If the breasts are not of an apparently equal amounts of BPE, the breast with the most BPE should be used to categorize BPE. In the event that treatment has altered BPE in one or both breasts, this can be reported. Although there may be considerable variation in visually estimating BPE, categorizing based on percentages (and specifically into quartiles) is not recommended. Quantification of BPE volume and intensity on MRI may be feasible in the future, but we await publication of robust data on that topic before endorsing percentage recommendations. We recognize that there are variations in BPE distribution and morphology. However, we defer on recommending descriptions of distribution or morphology until additional data are available. Currently, BPE refers to the volume of enhancement and the intensity of enhancement. For consistency, BPE should be included for all patients, using the categories in [Table 4](#).

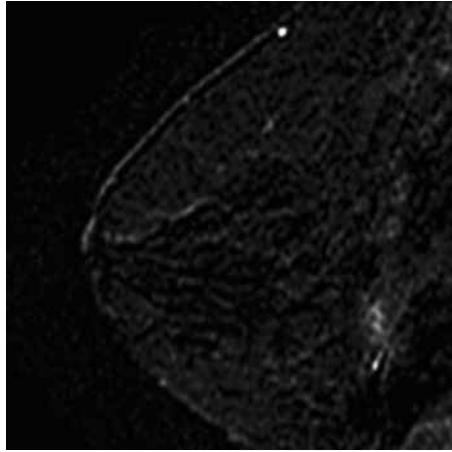


Figure 266 – Minimal.

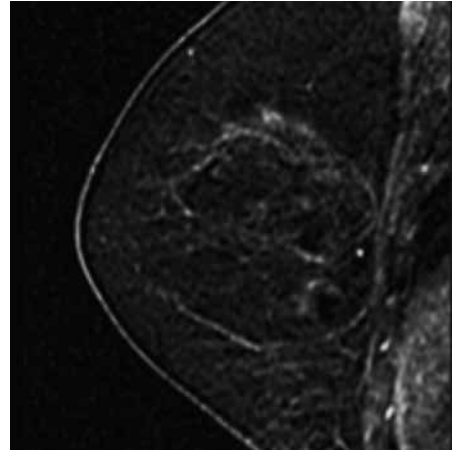


Figure 267 – Mild.

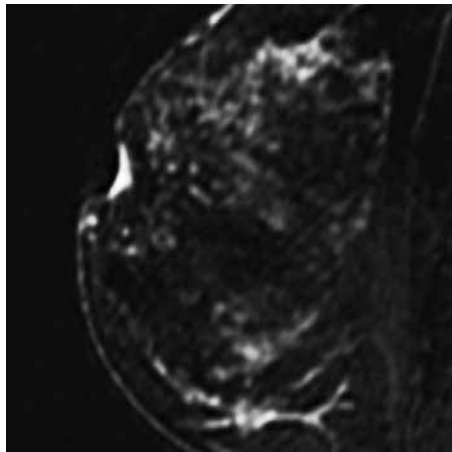


Figure 268 – Moderate.

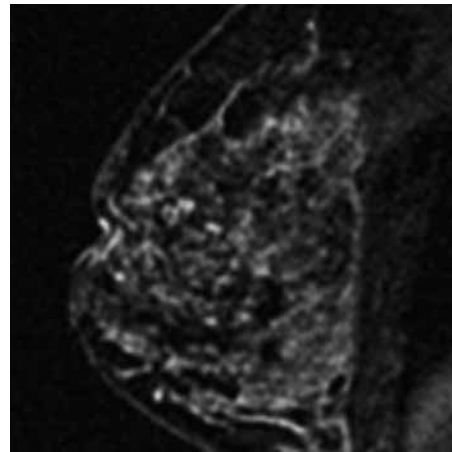


Figure 269 – Marked.

On bilateral scans, describe whether the pattern is asymmetric or symmetric, if appropriate. Asymmetric denotes more enhancement in one breast than in the other. Symmetric enhancement is mirror image.

c. Whether implants are present

If an implant is present, it should be so stated in the report. Information should include its composition (saline, silicone, or other) and the number of lumens (single or multiple).

4. CLEAR DESCRIPTION OF ANY IMPORTANT FINDINGS

Abnormal enhancement is unique and separate from BPE. Its description should indicate the breast in which the abnormal enhancement occurs, the lesion type, and modifiers.

The clinical location of the abnormality as extrapolated from the MRI location (based on clock-face position and quadrant location) should be reported. It should be recognized that there may be variation in location of a clinically detected lesion (patient is upright or supine), a mammographically detected lesion (patient is upright and compressed), a sonographically detected lesion (patient is supine or supine oblique), and an MRI-detected lesion (patient is prone) based on positional differences. A more consistent measurement is the distance from the nipple. It is encouraged that distance from the nipple for a lesion be reported in order to facilitate correlation between modalities, although it should be understood that one should expect some difference in distance from the nipple among the breast imaging modalities.

For bilateral axial examinations, the breasts should be pointing up, following the cross-sectional imaging convention.

The descriptors should include:

- a. Size
- b. Location
 - i. Right or left
 - ii. Breast quadrant and clock-face position (or central, retroareolar, and axillary tail descriptors)
 - iii. Distance from nipple, skin, or chest wall in centimeters (if applicable)

Descriptors for abnormal enhancement:

- c. Findings associated with abnormal enhancement include:
 - i. Artifacts that affect interpretation
 - ii. Focus: a tiny dot of enhancement that does not clearly represent a space-occupying lesion or mass and does not clearly show a mass on precontrast imaging.
 - iii. Masses: space-occupying lesions, usually spherical or ball-like, may displace or retract surrounding breast tissue

Descriptors — modifiers describing a mass:

- (a) Shape: describes the overall morphology of the enhancement
 - Oval (includes lobulated)
 - Round
 - Irregular
- (b) Margin: describes the borders
 - Circumscribed
 - Not circumscribed
 - Irregular
 - Spiculated

(c) Internal enhancement characteristics

- Homogeneous
- Heterogeneous
- Rim enhancement
- Dark internal septations

iv. Non-mass enhancement (NME): modifiers describing enhancement patterns with a specific MRI pattern

(a) Distribution

- Focal
- Linear
- Segmental
- Regional
- Multiple regions
- Diffuse

(b) Internal enhancement patterns (for all other types)

- Homogeneous
- Heterogeneous
- Clumped
- Clustered ring

v. Intramammary lymph node (rarely important)

vi. Skin lesion (rarely important)

vii. Non-enhancing findings

- (a) Ductal precontrast high signal on T1W
- (b) Cyst
- (c) Postoperative collections (hematoma/seroma)
- (d) Post-therapy skin thickening and trabecular thickening
- (e) Non-enhancing mass
- (f) Architectural distortion
- (g) Signal void from foreign bodies, clips, etc.

viii. Associated features

- (a) Nipple retraction
- (b) Nipple invasion
- (c) Skin retraction

- (d) Skin thickening
- (e) Skin invasion
 - Direct invasion
 - Inflammatory cancer
- (f) Axillary adenopathy
- (g) Pectoralis muscle invasion
- (h) Chest wall invasion
- (i) Architectural distortion
- ix. Fat-containing lesions
 - (a) Lymph nodes
 - Normal
 - Abnormal
 - (b) Fat necrosis
 - (c) Hamartoma
 - (d) Postoperative seroma/hematoma with fat
- x. Stability: describe how the enhancement changed (if new, stable, or changed in size from previous examination)
- xi. Kinetic curve assessment (if applicable)
 - (a) The fastest enhancing portion of the lesion or the most suspicious washout curve pattern in the lesion should be assessed
 - Sample fast enhancing areas
 - Sample for and report on the worst looking kinetic curve shape
 - (b) Signal intensity/time curve
 - Initial enhancement phase – describes the enhancement pattern within the first 2 minutes or when the curve starts to change
 - Slow
 - Medium
 - Fast
 - Delayed phase – describes the enhancement pattern after 2 minutes or after the curve starts to change
 - Persistent
 - Plateau
 - Washout

xii. Implants

(a) Implant material and lumen type

- Saline
- Silicone
 - Intact
 - Ruptured
- Other implant material (such as soy oil, polypropylene, polyurethane, and sponges; includes direct injections)
- Lumen type

(b) Implant location

- Retroglandular
- Retropectoral

(c) Abnormal implant contour

- Focal bulge

(d) Intracapsular silicone findings

- Radial folds
- Subcapsular line
- Keyhole sign (teardrop, noose)
- Linguine sign

(e) Extracapsular silicone

- Breast
- Lymph nodes

(f) Water droplets

(g) Peri-implant fluid

Also, we recognize that other techniques may be used in the evaluation of breast lesions. Newer and evolving techniques are constantly being introduced. Findings from other techniques, such as diffusion-weighted imaging or MR spectroscopy, should be reported if clinically important.

5. COMPARISON TO PREVIOUS EXAMINATION(S)

Include a statement indicating that the current examination has been compared to previous examination(s) with specific date(s). If this is not included, it should be assumed that no comparison has been made; however, it is preferable to indicate explicitly that no comparison was made. Comparison to a previous examination may assume importance if the finding of concern requires an evaluation of change or stability. Comparison is less important when the finding has characteristically benign features. Comparison may be irrelevant if the finding is inherently suspicious for malignancy. Information in this area should include:

- a. Previous MRI — date of examination
- b. Other imaging studies (mammogram, US, nuclear medicine examination, other) and date of examination

6. ASSESSMENT

This is a description of an overall summary of MRI findings, including assessment.

Incorporating an assessment category in the overall summary of the breast MRI report is sound medical practice. All final impressions should be complete with each lesion fully categorized.

An incomplete assessment (category 0) is used when full diagnostic imaging has not been performed and should be given only when additional imaging or clinical evaluation is recommended to establish the benignity of a finding (e.g., a possible intramammary lymph node or fat necrosis at MRI may require additional mammography and/or US examination).

Interpretation is facilitated by recognizing that almost all MRI examinations may be classified into a few assessment categories, listed in the section on [Assessment Categories](#). (See page 137)

7. MANAGEMENT

This is a description of patient management recommendations, as appropriate.

If an incomplete assessment (category 0) is rendered, a specific suggestion for the next course of action should be given (physical examination, diagnostic mammography, targeted diagnostic US, etc.). Note that an incomplete assessment (category 0) should not be rendered when recommending targeted US in order to determine the feasibility of performing biopsy using sonographic guidance; such a scenario requires the use of a category 4 or 5 assessment (suspicious or highly suggestive of malignancy).

If a suspicious abnormality is detected, the report should indicate that a biopsy should be performed in the absence of clinical contraindication. This means that the radiologist has sufficient concern that a biopsy is warranted; the term “clinical contraindication” indicates that there may be reasons why the patient and her physician might wish to defer the biopsy.

B. ASSESSMENT CATEGORIES

The assessment categories are based on BI-RADS® categories developed for mammography.

Table 5. Concordance Between BI-RADS® Assessment Categories and Management Recommendations.

Assessment	Management	Likelihood of Cancer
Category 0: Incomplete — Need Additional Imaging Evaluation	Recommend additional imaging: mammogram or targeted US	N/A
Category 1: Negative	Routine breast MRI screening if cumulative lifetime risk \geq 20%	Essentially 0% likelihood of malignancy
Category 2: Benign	Routine breast MRI screening if cumulative lifetime risk \geq 20%	Essentially 0% likelihood of malignancy
Category 3: Probably Benign	Short-interval (6-month) follow-up	\geq 0% but \leq 2% likelihood of malignancy
Category 4: Suspicious	Tissue diagnosis	$>$ 2% but $<$ 95% likelihood of malignancy
Category 5: Highly Suggestive of Malignancy	Tissue diagnosis	\geq 95% likelihood of malignancy
Category 6: Known Biopsy-Proven Malignancy	Surgical excision when clinically appropriate	N/A

1. ASSESSMENT IS INCOMPLETE

Category 0: Incomplete — Need Additional Imaging Evaluation

Use this for a finding that needs additional imaging evaluation. This may be used for a technically unsatisfactory scan or when more information is needed to interpret the scan. A recommendation for additional imaging evaluation might involve a repeat MRI with satisfactory technique or obtaining information with other imaging modalities (mammographic views, US, etc.). The radiologist should use judgment in how vigorously to pursue previous studies.

Every effort should be made not to use category 0. The reason for this is that almost always there is enough information on the initial breast MRI examination to provide a management recommendation. In general, the decision to biopsy or not may be made on the basis of the existing MRI study. A situation in which a final assessment of 0 may be helpful is when a finding on MRI is suspicious, but demonstration that the finding is characteristically benign on an additional study would avert biopsy. For example, if a small mass is suspicious on MRI but there is a possibility that it may represent a benign finding, such as an intramammary lymph node, then a category 0 assessment may be made, with the recommendation for targeted US (that might demonstrate characteristically benign features) to possibly avert biopsy. Another example would be a suspicious finding at MRI that may represent fat necrosis, with the recommendation for diagnostic mammography (that might demonstrate characteristically benign features) to possibly avert biopsy. If a category 0 assessment is rendered at MRI, detailed recommendations should describe the subsequent diagnostic imaging workup and the level of suspicion (pertinent in case the additional imaging does not establish benignity).

When additional studies are completed, a final assessment is rendered. If the additional studies are described in the same report, separate paragraphs indicating the pertinent findings from each imaging study will contribute to the final integrated assessment that takes all the findings into consideration.

2. ASSESSMENT IS COMPLETE — FINAL ASSESSMENT CATEGORIES

Category 1: Negative

There is nothing to comment on. This is a normal examination.

No abnormal enhancement was found; routine follow-up is advised. There is nothing to comment on. The breasts are symmetric, and no enhancing masses, architectural distortion, or suspicious areas of enhancement are present.

Category 1 includes a normal description of breast composition (amount of FGT) and the degree of BPE. It should be emphasized that BPE is a normal finding, and short-term follow-up is not necessary to assess BPE for stability.

Category 2: Benign

Like category 1, this is a normal assessment, but here the interpreter chooses to describe a benign finding in the breast MRI report. The interpreter may describe a benign finding such as: intramammary lymph node, implants, metallic foreign bodies (such as core biopsy and surgical clips), enhancing and non-enhancing fibroadenomas, cysts, old non-enhancing scars or recent scars; postoperative collections, fat-containing lesions (such as oil cysts, lipomas, galactoceles, and hamartomas). On the other hand, the interpreter may choose not to describe such findings, in which case the examination should be assessed as negative (category 1). Both category 1 and 2 assessments indicate that there is no evidence of malignancy. The difference is that category 2 should be used when describing one or more specific benign MRI findings in the report, whereas category 1 should be used when no such findings are described (even if such findings are present).

The committee supports a directive for annual follow-up MRI and mammography after either a category 1 or 2 screening MRI assessment, in line with established guidelines for high-risk screening.

Category 3: Probably Benign

A finding assessed using this category should have a $\leq 2\%$ likelihood of malignancy, but greater than the essentially 0% likelihood of malignancy of a characteristically benign finding. A probably benign finding is not expected to change over the suggested period of imaging surveillance, but the interpreting physician prefers to establish stability of the finding before recommending management limited to routine breast screening.

Although data are becoming available that shed light on the efficacy of short-interval follow-up for selected MRI findings, at the present time, such management recommendations are based on limited data. The use of a probably benign (category 3) assessment is reserved for specific findings that are separate from the BPE and are very likely benign. The use of a category 3 assessment has been intuitive in the past; however, there are several studies.^{1,2,3} that specifically address rates of malignancy and, to a very limited extent, types of lesions. Although these studies examined different populations of patients, several of them were able to demonstrate a $\leq 2\%$ malignancy rate, demonstrating the feasibility of using category 3 assessments at MRI. However, none of the studies provided PPVs for specific types of lesions, **so the use of category 3 assessment at MRI remains intuitive for radiologists who lack extensive (audited) personal experience with any given specific type of lesion.** Currently, this is an evolving area that needs the support of robust data before an unqualified endorsement is made to use category 3 assessments at MRI.

As at mammography, if a probably benign finding is smaller or less prominent (i.e., less contrast enhancement) on follow-up examination, the finding should be assessed as benign (category 2), eliminating the need for continued surveillance imaging. When a finding that otherwise meets probably benign imaging criteria is either new or has increased in size, extent, or conspicuity, then a recommendation for biopsy would be prudent and a recommendation for follow-up should not be rendered.

BPE, a benign finding on nearly all MRI examinations, should not be the reason for a probably benign assessment. However, if findings cannot be ascribed to normal variation of BPE and there is a question about whether observed enhancement could be transient and related to the hormonal status of the patient, then a probably benign (category 3) assessment with a recommendation to return for very-short-interval follow-up (2–3 months) may be appropriate.

Because a benign hormonal enhancement can vary from cycle to cycle, a category 3 assessment may be used for the menstruating patient who was scanned in a suboptimal phase of her cycle; a follow-up MRI examination should be scheduled for the optimal (week 2) phase of her cycle. Additionally, a category 3 assessment may be used for the post-menopausal patient who is on hormone replacement therapy (HRT) and in whom probable hormonal enhancement is observed. Stopping HRT for several weeks and repeating the scan may be warranted in this scenario. It should be emphasized that unexplained areas of enhancement that are demonstrated to be due to HRT are uncommon. As with mammography, if the finding is smaller or less prominent (i.e., less contrast enhancement) at follow-up examination, the finding is benign.

Recommendations will likely undergo future modifications as more data accrue regarding the validity of using category 3 assessments at MRI, the follow-up interval required, and the type of findings that should be followed.

Follow-up of Foci

Foci are defined as small dots of enhancement that are unique and stand out from the BPE. They are too small to be accurately assessed with respect to margin or internal enhancement. Indeed, if margin or internal enhancement can be assessed, the finding should be considered a small mass and not a focus. New foci or foci that have increased in size should be viewed with suspicion and carefully evaluated.

Correlation with bright-fluid imaging (T2W imaging or STIR imaging) can be helpful in the evaluation of a focus. If a correlate is uniformly very high in signal intensity or if cyst-like features are identified, the focus may be assessed as benign. (Most of these foci represent lymph nodes or small myxomatous fibroadenomas.) However, if the focus does not have a very high signal correlate on bright-fluid imaging, then the focus may or may not be benign. These foci may be followed or biopsied. In certain cases (if the finding is new or increased in size) the focus always should be biopsied. Note that malignant foci may be brighter than the surrounding FGT, although they do not usually appear cyst-like.

Follow-up of Masses

Masses that enhance and are identified on an initial MRI examination should undergo assessment based on morphology and kinetics. It has been documented that occasionally malignancy may demonstrate benign-appearing MRI features, such as an oval or round shape with a circumscribed margin and homogeneous internal enhancement. Therefore, in a scenario in which the stability of the finding is unknown, periodic surveillance imaging may be appropriate, depending on various factors that affect the prior probability of malignancy (age, cancer risk, etc.) as well as the patient's willingness to accept surveillance imaging as an alternative to

biopsy, given less than robust data that support a watchful waiting approach. If surveillance imaging is undertaken, an increase in size of the mass should prompt immediate biopsy.

Follow-up of NME

NME that is unique and separate from the overall background enhancement should undergo assessment based on morphology and kinetics. Bright-fluid imaging sequences can be helpful in these instances to demonstrate any associated cysts, which may support a diagnosis of focal fibrocystic change and a benign (category 2) assessment. However, limited data on linear, clumped, and segmental enhancement indicate that these findings should not be followed, as the malignancy rate appears to be greater than 2%.⁴ At this time, the literature is not sufficiently robust to endorse the use of a category 3 assessment for NME.

Timing of Follow-up

Final assessment category 3 is best used for a unique focal finding and managed with an initial short-interval follow-up (6 months) examination followed by additional examinations until long-term (2- or 3-year) stability is demonstrated. For category 3 assessments, the initial short-term follow-up interval is usually 6 months, involving the breast(s) containing the probably benign finding(s). Assuming stability at this 6-month examination, a category 3 assessment again will be rendered with a management recommendation for a second short-interval follow-up examination in 6 months, but now involving both breasts if the opposite breast will be due for routine annual screening. Again assuming stability at this second short-interval follow up, the examination is once more assessed as category 3, but now the recommended follow-up interval usually is lengthened to 1 year due to the already-observed 12-month stability. The recommended 2- or 3-year follow-up in these cases is: 6 months, 6 months, 1 year, and, optionally, 1 more year to establish stability. After 2 to 3 years of stability, the finding should be assessed as benign (category 2). It should be emphasized that this approach is borrowed from mammography. While the vast majority of probably benign findings are managed with follow-up, there may be occasions in which biopsies are done instead (patient preference or overriding clinical concern). As with any interpretive examination, a less experienced reader may conclude that a finding such as benign BPE, for example, should be classified as category 3. A more experienced reader may recognize this as normal or benign at 6 or 12 months and classify it as category 1 or 2. With a properly worded report, the assessment category may then be changed to one that the current reader feels is appropriate, even though long-term stability has not been demonstrated.

It is imperative that surveillance imaging does not alter the stage at diagnosis or prognosis of the few patients with malignancies who are given category 3 assessments. Because this has not yet been demonstrated for MRI, as it has been for mammography, careful auditing of the use of category 3 assessments is necessary, and publication of outcomes data is strongly recommended. Although the data are not robust, it appears the $\leq 2\%$ malignancy rate already demonstrated at mammographic follow-up also may be achieved at MRI. Several recent publications have demonstrated that focal lesions assigned to category 3 had a $\leq 2\%$ malignancy rate, albeit without use of specific BI-RADS[®] MRI descriptors for the lesions included in the studies.^{5,6,7} Publication of outcomes data for specific category 3 lesions, using BI-RADS[®] MRI, is strongly recommended. It should be noted that a $\leq 2\%$ malignancy rate may be difficult to achieve due to the high-risk population that usually is studied by MRI (higher than average prior probability of cancer).

A desirable goal for the frequency of making category 3 assessments at MRI is less than 10%. Over time, this rate should decrease to the point that a mature program should demonstrate

a rate much closer to the approximately 1%–2% rate currently achieved at mammography, especially as the availability of previous examination(s) increases. A decrease in the frequency of category 3 assessments and false-positive outcomes has been demonstrated in the breast MRI literature as experience is gained.

Category 4: Suspicious

This category is reserved for findings that do not have the classic appearance of malignancy but are sufficiently suspicious to justify a recommendation for biopsy. The ceiling for a category 3 assessment is a 2% likelihood of malignancy and the floor for a category 5 assessment is 95%, so category 4 assessments cover the wide range of likelihood of malignancy in between. Thus, almost all recommendations for breast interventional procedures will come from assessments made using this assessment category. In breast MRI, assessment category 4 is not currently divided into subcategories 4A, 4B, and 4C.

Category 4 is used for the majority of findings prompting breast intervention, which can be performed by percutaneous biopsy, by US or stereotactic guidance, or by MRI guidance for lesions not visible at either US or mammography. As cysts rarely pose a problem in interpretation at MRI, diagnostic aspiration is not commonly performed. In many patients with a suspicious abnormality at MRI, targeted US will identify a corresponding abnormality so that US-guided biopsy can be performed. US-guided biopsies are faster, more comfortable for the patient, and more cost effective than MRI-guided biopsies. There are no established guidelines on who should undergo targeted US. However, in general, patients with masses larger than 5 mm should be examined by targeted US if the MR appearance is suspicious. Areas of NME may be evident on US as well, thus bringing the radiologist's judgment into play. Factors that may limit visibility at US include fatty breasts, extremely complex breasts with multiple cysts, very large breasts, and very deep lesions. If there is any question about whether a presumed sonographic correlate actually is the same as the suspicious MRI lesion, MR-guided biopsy is advised.

Category 5: Highly Suggestive of Malignancy

These assessments carry a very high probability ($\geq 95\%$) of malignancy. This category initially was established to include lesions for which 1-stage surgical treatment was considered without preliminary biopsy, in an era when preoperative wire localization was the primary breast interventional procedure. Nowadays, given the widespread acceptance of imaging-guided percutaneous biopsy, 1-stage surgery rarely if ever is performed. Rather, current oncologic management almost always involves tissue diagnosis of malignancy via percutaneous tissue sampling. This facilitates treatment options, such as when sentinel node biopsy is included in surgical management or when neoadjuvant chemotherapy is administered prior to surgery. Therefore, the current rationale for using category 5 assessment is to identify lesions for which any nonmalignant percutaneous tissue diagnosis is considered discordant, resulting in a recommendation for repeat (usually surgical) biopsy.

No single MRI descriptor is sufficiently predictive of malignancy to produce the $\geq 95\%$ probability required for a category 5 assessment. Just as in mammography and US, an appropriate combination of suspicious findings is needed to justify a category 5 assessment at MRI. It is recommended that category 5 assessments be audited separately to verify a $\geq 95\%$ PPV, thereby validating that the assessment is not being overused.

Category 6: Known Biopsy-Proven Malignancy

This category is reserved for examinations performed after biopsy proof of malignancy (imaging performed after percutaneous biopsy) but prior to surgical excision, in which there are no abnormalities other than the known cancer that might need additional evaluation. That is, a cancer diagnosis has already been established, a lesion is depicted at MRI, and this lesion corresponds to the previously biopsied cancer.

A category 6 is not appropriate following successful lumpectomy or mastectomy (margin of resection free of tumor). The rationale for establishing category 6 is exclusion of these cases from auditing, because additional malignancy is frequently found such that auditing these cases would inappropriately skew overall outcomes. In the event that the breast with known cancer has a separate suspicious MRI finding that requires biopsy for diagnosis, the appropriate category 4 or 5 assessment should be rendered, and this would be the overall assessment because it leads to more prompt intervention.

C. WORDING THE REPORT

The current examination should be compared to prior examinations when appropriate. The indication for examination, such as screening or diagnostic, should be stated. The report should be organized with a brief description of the composition of the breast and any pertinent findings, followed by the assessment and management recommendations. All discussions between the interpreting physician and the referring clinician or patient should be documented in the original report or in an addendum to the report.

The report should be succinct, using terminology from the approved lexicon without embellishment. Do not use definitions of the lexicon terms in the report narrative; use only the descriptors themselves. Following the impression section and the (concordant) management recommendations section of the report, the terminology for the assessment category should be stated, as well as its category number. Other aspects of the report data should comply with the [ACR Practice Guideline for Communication: Diagnostic Radiology](#).

REFERENCES

1. Weinstein SP, Hanna LG, Gatsonis C, Schnall MD, Rosen MA, Lehman CD. [Frequency of malignancy seen in probably benign lesion at contrast-enhanced breast MR imaging: findings from ACRIN 6667](#). *Radiology* 2010; 255:731–7.
2. Eby PR, DeMartini WB, Peacock S, Rosen EL, Lauro B, Lehman CD. [Cancer yield of probably benign breast MR examinations](#). *J Magn Reson Imaging* 2007; 26:950–5.
3. Kriege M, Brekelmans CTM, Boetes C, et al. [Efficacy of MRI and mammography for breast-cancer screening in women with a familial or genetic predisposition](#). *N Engl J Med* 2004; 351:427–37.
4. Liberman L, Morris EA, Dershaw DD, Abramson AF, Tan LK. [Ductal enhancement on MR imaging of the breast](#). *AJR* 2003; 519–25.
5. Mahoney MC, Gatsonis C, Hanna L, DeMartini WB, Lehman CD. [Positive predictive value of BI-RADS MR imaging](#). *Radiology* 2012; 264:51–8.
6. Eby PR, DeMartini WB, Gutierrez RL, Lehman CD. [Probably benign lesions detected on breast MR imaging](#). *Magn Reson Imaging Clin N Am* 2010; 18:309–21.
7. Warner E, Plewes DB, Hill KA, Causer PA, et al. [Surveillance of BRCA 1 and BRCA 2 mutation carriers with magnetic resonance imaging, ultrasound, mammography, and clinical breast examination](#). *JAMA* 2004; 292:1317–25.