



EANM practice guideline/SNMMI procedure standard for RAIU and thyroid scintigraphy

Luca Giovanella^{1,2} · Anca M. Avram³ · Ioannis Iakovou⁴ · Jennifer Kwak⁵ · Susan A. Lawson³ · Elizabeth Lulaj⁶ · Markus Luster⁷ · Arnoldo Piccardo⁸ · Matthias Schmidt⁹ · Mark Tulchinsky¹⁰ · Frederick A. Verburg⁷ · Ely Wolin¹¹

Received: 11 July 2019 / Accepted: 29 July 2019 / Published online: 7 August 2019
© Springer-Verlag GmbH Germany, part of Springer Nature 2019

Abstract

Introduction Scintigraphic evaluation of the thyroid gland enables determination of the iodine-123 iodide or the ^{99m}Tc-pertechnetate uptake and distribution and remains the most accurate method for the diagnosis and quantification of thyroid autonomy and the detection of ectopic thyroid tissue. In addition, thyroid scintigraphy and radioiodine uptake test are useful to discriminate hyperthyroidism from destructive thyrotoxicosis and iodine-induced hyperthyroidism, respectively.

Methods Several radiopharmaceuticals are available to help in differentiating benign from malignant cytologically indeterminate thyroid nodules and for supporting clinical decision-making. This joint practice guideline/procedure standard from the European Association of Nuclear Medicine (EANM) and the Society of Nuclear Medicine and Molecular Imaging (SNMMI) provides recommendations based on the available evidence in the literature.

Conclusion The purpose of this practice guideline/procedure standard is to assist imaging specialists and clinicians in recommending, performing, and interpreting the results of thyroid scintigraphy (including positron emission tomography) with various radiopharmaceuticals and radioiodine uptake test in patients with different thyroid diseases.

Keywords Thyroid · Scintigraphy · Radioiodine uptake test · ^{99m}Tc-sestaMIBI, ¹⁸F-fluorodeoxyglucose

Preamble

The Society of Nuclear Medicine and Molecular Imaging (SNMMI) and European Association of Nuclear Medicine (EANM) are international scientific and professional organizations which promote the science, technology, and practical applications of nuclear medicine. These professional societies periodically define new guidelines for nuclear medicine practice to help advance the science of nuclear medicine and to improve the quality of service for patients. Each practice guideline represents a policy statement by these organizations and has undergone a consensus process in which it has been subjected to extensive review, requiring the

approval of the Committee on Guidelines and Board of Directors of both organizations. Both SNMMI and EANM recognize that the safe and effective use of diagnostic nuclear medicine imaging requires specific training, skills, and techniques, as described in the document. These guidelines are an educational tool designed to assist practitioners in providing appropriate care for patients. They are not inflexible rules or requirements of practice and are not intended, nor should they be used, to establish a legal standard of care. The ultimate judgment regarding any specific procedure or course of action must be made by the physician in light of all the circumstances presented. The variety and complexity of human conditions make it impossible to always reach the most appropriate diagnosis or to predict with certainty a particular response to treatment. Therefore, it should be recognized that adherence to these guidelines will not guarantee an accurate diagnosis or a successful outcome. All that should be expected is that the practitioner will follow a reasonable course of action based on current knowledge, available resources, and the needs of the patient to deliver effective and safe medical care.

Anca M. Avram is the co-chairs

This article is part of the Topical Collection on Endocrinology

✉ Luca Giovanella
Luca.Giovanella@eoc.ch

Extended author information available on the last page of the article

Introduction

Normal thyroid tissue is characterized by the unique capability of its follicular cells to trap and to process iodine (I^2) which is subsequently incorporated in thyroglobulin (Tg)-bound thyroid hormones. The iodine uptake into the follicular cells is executed by the sodium-iodide symporter (NIS), a transmembrane protein located on the basolateral membrane of the thyroid follicular cells which functions as an energy ($Na^+/K^+ -ATPase$)-dependent co-transport mechanism [1]. Under physiological conditions, the expression and activity of NIS are regulated by thyrotropin (thyroid-stimulating hormone, TSH) and modulated by cytokines such as TNF or TGF- β . Iodide (I^-) is the ionized form of iodine and it is translocated via an ionic channel across the apical membrane into the colloid, with pendrin (an anion exchange protein) playing a major role in this process [2]. Finally, the iodide oxidation into iodine and iodine organification into tyrosyl residues on the Tg molecule takes place at the outer (luminal) surface of the apical membrane of the epithelium. Because iodine plays a major role in the physiology and pathophysiology of the thyroid gland, iodine, or iodine analogues (i.e., NIS-targeting radiopharmaceuticals) are well suited for thyroid imaging and radioiodine uptake (RAIU) study. Additionally, imaging with specific tracers such as ^{99m}Tc -sestamibi (^{99m}Tc -MIBI) and ^{18}F -fluorodeoxyglucose (^{18}F FDG) may be useful in selected cases to help in discriminating benign from malignant thyroid nodules [3].

Goals

Thyroid scintigraphy with NIS-targeting tracers is used for the detection and localization of focal and/or diffuse abnormalities of follicular thyroid cells. The radioiodine uptake test (RAIU) quantifies the global iodine metabolism within the thyroid gland as reflected by the radiopharmaceutical accumulation by, and kinetics within, the thyroid gland. Thyroid imaging with ^{99m}Tc -sestamibi and ^{18}F FDG provide information about the biological behavior of cytologically indeterminate thyroid nodules (i.e., aggressive vs. indolent) [3–8].

Radiopharmaceuticals

The thyroid gland actively traps iodide producing a concentration gradient of up to 20:1 to plasma. Based on physiologic iodine metabolism within the thyroid gland, ^{123}I -sodium (sodium) iodide ($^{123}I^-$) is considered an ideal radiopharmaceutical for assessing NIS function and iodide

organification during thyroid hormone synthesis, due to its gamma emission of 159 KeV resulting in optimal imaging quality. ^{99m}Tc -sodium (sodium) pertechnetate ($^{99m}TcO_4^-$) is a pharmacologic mimic of iodine which is concentrated within the thyroid cells by NIS activity; however, it is not organified and therefore washout from thyroid cells occurs after 30 min of radiotracer injection. $^{99m}TcO_4^-$ is the tracer most commonly used for thyroid scintigraphy. Compared with $^{123}I^-$, $^{99m}TcO_4^-$ has the advantages of daily availability in every nuclear medicine department, lower cost and shorter physical half-life (6 h vs. 13 h). In addition, since ^{99m}Tc is a pure gamma emitter with a short half-life, relatively large amounts of activity can be given without imparting a large radiation dose to the thyroid. Then, high-quality images are obtained due to the high flux and favorable energy of the gamma photons. However, $^{99m}TcO_4^-$ reflects only thyroid trapping ability as it does not undergo further metabolism and gradually leaks out of the thyroid gland. Thus, for scintigraphy with $^{99m}TcO_4^-$, images are obtained early (within 30 min of radiotracer administration). Although the thyroid gland does not organify $^{99m}TcO_4^-$, in the majority of cases, the uptake and imaging data provide sufficient information for accurate diagnosis of thyroid conditions. However, in very rare cases, the appearance of a thyroid nodule may be discordant on radioiodine and pertechnetate scans due to iodide organification defects in the nodule that results in a rapid washout of radioiodine (i.e., so-called “trapping only nodule”) [9]. All in all, $^{123}I^-$ and $^{99m}TcO_4^-$ each have unique advantages and disadvantages for thyroid imaging. Since cost and availability may limit more widespread use of $^{123}I^-$, $^{99m}TcO_4^-$ remains the agent of choice in many nuclear medicine departments. $^{123}I^-$ scintigraphy is the agent considered for children and on special request when an organification defect is suspected, while $^{99m}TcO_4^-$ is preferred when the patient is lactating because of the shorter physical half-life of ^{99m}Tc .

^{99m}Tc -sestamibi is a lipophilic cation that crosses the cell membrane and penetrates reversibly into the cytoplasm via thermodynamic driving forces and then irreversibly passes the mitochondrial membrane along an electrical gradient characterized by a high negative inner membrane potential. The cancer cells, with their greater metabolic turnover, are characterized by a higher electrical gradient of the mitochondrial membrane, leading to increased accumulation of ^{99m}Tc -sestamibi compared to normal cells [10].

^{18}F FDG is able to trace an accelerated glucose metabolism in the thyroid tissue as in the other principal organs. The ^{18}F FDG uptake mechanism is mediated by an upregulation of transmembrane glucose transporter proteins (GLUTs), able to introduce the tracer into the cell, and by an overexpression of hexokinases (HK) able to phosphorylate ^{18}F FDG to ^{18}F FDG-6-phosphate, and thus trapping the tracer in the cell [10].

Indications and contraindications

Indications

A. Thyroid scintigraphy is useful for evaluating the following:

1. Size and location of thyroid tissue
2. Abnormal thyroid function consistent with overt or subclinical hyperthyroidism
3. Differentiation of hypoechogenic thyroids according to low and high thyroid uptake
4. Suspected focal masses or diffuse thyroid disease
5. Function of thyroid nodules detected on clinical examination and/or other imaging examinations
6. Evaluation of multinodular goiter to identify suspicious hypofunctional “cold” areas that require further evaluation with FNA-biopsy
7. Evaluation of multinodular goiter for hyperfunctional “hot” thyroid nodules prior to radioiodine ablation
8. Evaluation of thyroid nodules with indeterminate FNA-biopsy results (e.g., cytologically indeterminate nodules) to identify a benign AFTN (including “compensated” ones)
9. Proliferation/metabolism of hypofunctioning thyroid nodules with indeterminate FNA biopsy results (e.g., cytologically indeterminate cold nodules) to identify those at higher risk of malignancy)
10. Thyroid ectopia and diagnostic work-up of congenital hypothyroidism

B. Radioiodine thyroid uptake (RAIU) is useful for the following:

1. Differentiating hyperthyroidism from other forms of thyrotoxicosis (e.g., destructive thyroiditis, factitious thyrotoxicosis, and iodine overload)
2. Detecting iodine organification defects with the perchlorate discharge test

RAIU testing is also useful for calculating the administered therapeutic activity of radioiodine to treat hyperthyroidism and euthyroid multinodular goiter. This is, however, outside the scope of the present document and our readers are referred to specific EANM guidelines/SNMMI procedure guidelines [11, 12].

Evaluation and differential diagnosis of hyperthyroidism

Determining the etiology of abnormal thyroid function establishes the correct diagnosis and adequate treatment of thyroid disease. Both thyroid scintigraphy and RAIU testing are used to differentiate between *productive thyrotoxicosis* (i.e., hyperthyroidism) vs. *destructive thyrotoxicosis* (i.e.,

acute and subacute thyroiditis) and *factitious thyrotoxicosis*. Thyroid scintigraphy may easily differentiate productive from destructive thyrotoxicosis, and diffuse from focal overactivity within the thyroid gland. The common features of productive thyrotoxicosis (i.e., “true” hyperthyroidism) are as follows:

- Diffuse thyroid overactivity with a homogeneous distribution of the tracer, reduced uptake in major salivary glands, and low background, consistent with Graves’ disease.
- Unifocal or multifocal overactive areas with reduced or suppressed uptake in the remaining thyroid tissue, consistent with autonomously functioning thyroid nodule(s).
- Multiple mixed areas of focal increased and suppressed uptake, consistent with toxic multinodular goiter.

On the other hand, decreased uptake is typically observed in early phases of destructive thyroiditis, factitious thyrotoxicosis, or in the presence of exogenous iodine overload. Because of high iodine loading from amiodarone therapy, both iodine trapping and organification within the thyroid gland are reduced and the traditional thyroid imaging agents ($^{99m}\text{TcO}_4^-$, $^{123}\text{I}^-$) are not useful for further characterization of amiodarone-induced thyrotoxicosis (AIT) as *type 1*, caused by increased thyroid hormone production due to amiodarone-induced iodine oversupply on a background of non-toxic multinodular goiter, vs. *type 2*, caused by increased release of thyroid hormones due to amiodarone-induced thyroid gland inflammation, which has management implications. However, this differential diagnosis is possible using ^{99m}Tc -sestamibi thyroid scintigraphy, which demonstrates preserved thyroidal ^{99m}Tc -sestamibi uptake in type 1 AIT, and decreased thyroidal ^{99m}Tc -sestamibi uptake in type 2 AIT [13, 14].

Functional assessment of thyroid nodules identified on clinical examination and/or imaging

Thyroid nodules are common incidental findings on clinical examination and/or imaging studies, and thus it is necessary to decide which thyroid nodules carry a potential risk of malignancy and require further workup with fine-needle-aspiration (FNA) biopsy for definitive characterization. High-resolution thyroid ultrasound (US) provides an accurate assessment of sono-morphological nodule features which have been used to produce a standardized risk assessment for thyroid malignancy under thyroid imaging and data reporting system (TI-RADS) [15] (Fig. 1).

However, none of the TI-RADS criteria addresses the functional status of thyroid nodules, despite the fact that a scintigraphically hyperfunctioning (i.e., “hot”) thyroid nodule has a 96–99 % negative predictive value for malignancy [3, 16, 17]. Thyroid scintigraphy is the only examination able to

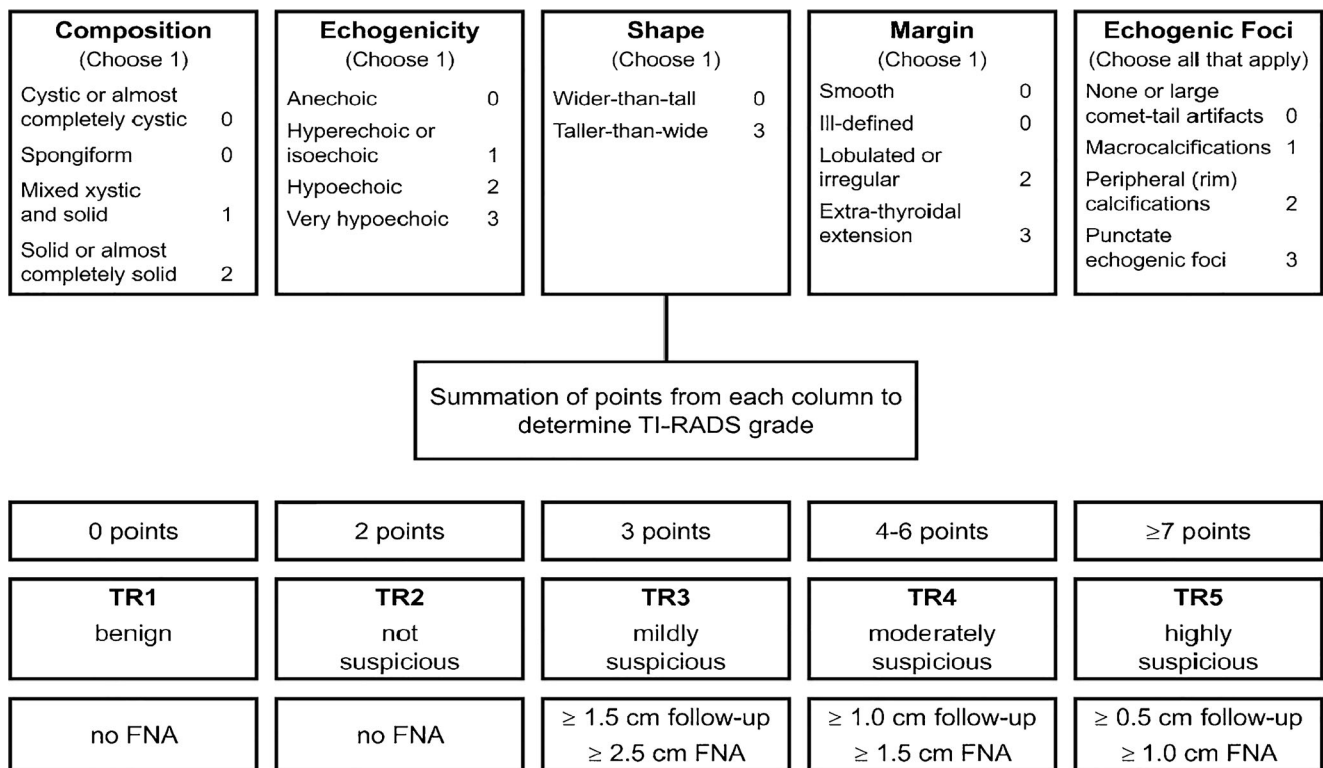


Fig. 1 American College of Radiology (ACR) TI-RADS classification of thyroid nodules and management recommendations

demonstrate the presence of autonomously functioning thyroid nodules (AFTN). Notably, while AFTN very rarely harbors malignancy, indeterminate cytology (e.g., Bethesda classes III and IV, see below) is frequently reported in these cases. Accordingly, current clinical guidelines suggest refraining from FNA biopsy of AFTN to avoid unnecessary invasive procedures, including surgical resection for definitive histopathologic diagnosis. In a study of 615 AFTN (size, 23.2 ± 10 mm), analyzed prospectively with TI-RADS based on US features, more than 80 % of AFTN were classified as TI-RADS ≥ 4 (i.e., moderately suspicious, requiring FNA for nodules ≥ 1.5 cm), only 16 % of AFTN were classified as TI-RADS ≤ 3 , and < 0.1 % of AFTN were classified as TI-RADS 5. Therefore, integration of thyroid scintigraphy into TI-RADS model is essential to prevent unnecessary FNA biopsies for nodules that demonstrate autonomy [18]. The relationship between thyroid autonomy and TSH levels is affected by the degree of iodine sufficiency and varies widely regionally [4, 19]. Consequently, variable indications are given in different clinical guidelines regarding the scintigraphic evaluation of thyroid nodules (Table 1). A thyroid scan is

recommended only when the TSH level is low or low-normal in the USA [20], while in Germany, it is recommended in all patients with a nodule > 10 mm, regardless of TSH levels [21]. Indeed, American Association of Clinical Endocrinologists (AACE), Associazione Medici Endocrinologi (AME), and European Thyroid Association (ETA) joint guidelines suggest the use of thyroid scans taking into account the iodine supply in different geographical areas [22]. Although most thyroid cancers are hypofunctioning and therefore appear as “cold” nodules on thyroid scintigraphy, the majority of the cold nodules are benign (up to 80–90 %), such that the specificity of this finding for the diagnosis of malignancy is low. Therefore, it is recommended that a hypofunctioning thyroid nodule is further evaluated with dedicated thyroid US and managed based on its sonographic features according to TI-RADS classification [15, 23].

The Bethesda System for Reporting Thyroid Cytopathology is a standardized reporting system for FNA biopsy of thyroid nodules that predicts the associated risk of malignancy based on cytological features. The reclassification of the non-invasive follicular variant of papillary

Table 1 Indications for scintigraphic evaluation of thyroid nodules in different clinical guidelines

ATA 2015	German Endocrine Surgeons 2011	AACE/AME/ETA 2010 and 2016
-Nodules > 10 – 15 mm -TSH subnormal	-Thyroid nodules > 10 mm - Any TSH	-TSH $<$ lower reference limit - Iodine deficiency: TSH < 1.0 – 1.5 mU/L

Table 2 The 2017 Thyroid Cytopathology Bethesda System and predicted risk of malignancy

Class	Diagnostic category	Cancer risk
I	Non-diagnostic (or unsatisfactory)	5 to 10 %
II	Benign	0 to 3 %
III	Atypia of undetermined significance (AUS) or follicular lesion of undetermined significance (FLUS)	10 to 30 %
IV	Follicular neoplasm (or suspicious for follicular neoplasm)	25 to 40 %
V	Suspicious for malignancy	50 to 75 %
VI	Malignant	97 to 99 %

thyroid carcinoma (non-invasive fvPTC) as non-invasive follicular thyroid neoplasm with papillary-like nuclear features (NIFTP) resulted in recalculation on the risk of malignancy in most recent 2017 Bethesda classification, since although NIFTP is no longer considered a thyroid carcinoma, surgery is nonetheless necessary for these nodules. (Table 2) [24].

Evaluation and management of thyroid nodules with indeterminate cytology

Thyroid nodules with indeterminate cytology are classified as a follicular lesion of undetermined significance or atypia of undetermined significance (FLUS/AUS, Bethesda class III) or follicular neoplasm (Bethesda class IV). The risk of malignancy ranges from 10 to 30 % (class III) to 25–40 % (class IV). Repeat FNA biopsy, molecular testing, molecular imaging (see below), or diagnostic lobectomy can be performed; however, it is reasonable to first perform thyroid scintigraphy (if not previously obtained), particularly if the TSH is in the lower end of the normal range (e.g., less than 1.5 mU/L) and only select patients with nonfunctioning nodules for molecular testing, molecular imaging, or diagnostic lobectomy [25]. There are three approaches to the molecular characterization of FNA aspirates: (1) mutational analysis, based on identification of particular molecular markers of malignancy, e.g., *BRAF*, *RAS*, *RET/PTC*, *PAX8/PPAR* gamma, *TERT*, *TP53* mutations, and copy number variations in 112 thyroid-related genes (ThyroSeq, version 1–3); (2) mRNA genomic sequencing classifier (GSC, Afirma) measuring the activity level of 167 genes within the thyroid nodule; (3) miRNA gene expression combined with mutational analysis (ThyraMIR and ThyGenX), which is a multiplatform test based on the expression level of 10 miRNA genes and mutational analysis to detect the presence of eight oncogenes. The results of these tests are reported as either *benign molecular pattern* (no mutations on mutational analysis or a benign GSC or miRNA gene expression classifier result) or *suspicious pattern* (detection of point mutations in genes that are strongly associated with thyroid cancer, e.g., *BRAF*, *TERT*, and *RET/PTC*), which require thyroid surgery for definitive diagnosis (estimated risk of

malignancy is 37 to 44 %) [26, 27]. The negative and positive predictive values of these tests are highly dependent on the prevalence of thyroid cancer in the population that is studied and, particularly, the negative predictive value decreases as the cancer prevalence increases (e.g., the negative predictive value of the test is greater in a population with lower a priori risk of malignancy, and a negative test is most reliable when the prevalence is < 30 %).

Molecular thyroid imaging using ^{99m}Tc -sestamibi and ^{18}F FDG allows evaluation of biological behavior and aggressiveness of hypofunctioning thyroid nodules. In the case of ^{99m}Tc -sestamibi-avid and/or ^{18}F FDG-avid nodules, the risk of malignancy is about 35 % [5, 7]. At the same time, a nodule characterized by low or absent ^{99m}Tc -sestamibi and/or ^{18}F FDG uptake is considered at a very low risk of malignancy [4, 28, 29]. Indeed, the high NPV of thyroid imaging with ^{99m}Tc -sestamibi or ^{18}F FDG is very helpful in characterizing nodules with indeterminate cytological results but also for nodules with repeatedly insufficient and non-diagnostic FNA results [3, 29]. Other indications for functional thyroid imaging with ^{99m}Tc -sestamibi and/or ^{18}F FDG include identification of a nodule at higher risk for malignancy in patients affected by large multinodular goiter, or with multiple nodules with the suspicious of US features for the guiding evaluation with FNA biopsy [3–8, 29].

Evaluation of patients with congenital hypothyroidism

Congenital hypothyroidism (CH) is a disorder characterized by inadequate thyroid hormone production and is the most common cause of preventable intellectual disability and growth failure. It affects approximately 1:2000 to 1:4000 newborns in iodine-sufficient regions, with a higher incidence in areas with iodine deficiency. Apart from iodine deficiency, the possible etiologies of CH include (1) thyroid dysgenesis (ectopia, hyperplasia, and agenesis); (2) defects in thyroid hormone synthesis (dyshormonogenesis); (3) hypothalamic-pituitary CH; (4) transient CH due to iodine overload, maternal anti-thyroid antibodies, or anti-thyroid drug intake during pregnancy [30]. Neonatal screening for CH by measurement of TSH and free or total T4 (performed between the second and fifth day of life) has been established for early detection

and prompt initiation of thyroid hormone replacement for preventing developmental retardation and neurological sequelae. Thyroid scintigraphy and thyroid sonography reveal the underlying etiology of CH [31]. Ultrasonography evaluates the presence of the thyroid gland and measures thyroid volume; however, it is less sensitive than scintigraphy for diagnosing thyroid ectopia [32] and thyroid dyshormonogenesis [33].

RAIU testing for differentiating productive from destructive and factitious thyrotoxicosis

RAIU is increased in productive thyrotoxicosis (hyperthyroidism associated with toxic diffuse goiter and toxic uni- or multinodular goiter), while destructive and factitious thyrotoxicosis are typically associated with low or suppressed RAIU (note: iodine contamination should be excluded before drawing a conclusion).

RAIU testing for detection of intrathyroidal defects of organification (perchlorate discharge test)

Iodine organification defects (IOD) present with high early uptake sensitive to perchlorate intake. In particular, a reduction > 10 % of the RAIU levels at 2 h after oral administration of sodium perchlorate is considered positive for an iodide organification defect. Patients with iodide discharge of 10 % to 90 % are considered to have a partial IOD, whereas patients with iodide discharge greater than 90 % are considered to have a total IOD, respectively [33].

Contraindications

For the pregnant and potentially pregnant patients, see that ACR Practice Guideline for imaging pregnant or potentially pregnant adolescents and women with ionizing radiation [34]. In women of childbearing age, it is necessary to verify the absence of pregnancy and lactation. Evaluation by ultrasonography is preferred in a pregnant (or possibly pregnant) patient. If medically justified, radiation exposure should be delayed until after pregnancy and breastfeeding [34].

Specifications of the procedures

Qualifications and responsibilities of personnel

All physicians and personnel involved in performing and reporting thyroid imaging and RAIU should be qualified and experienced in accordance with applicable laws, and individual responsibilities should be documented in standard operating procedures.

Request, examination planning, and patient preparation

The written or electronic request for thyroid imaging procedures and RAIU must be originated by a physician or other appropriately licensed health care provider. It should provide sufficient information to demonstrate the medical necessity of the examination and allow for its proper performance and interpretation. Documentation should include signs, symptoms, relevant clinical history (including medications), the results of all other relevant examinations performed, and the specific reason for the examination or a provisional diagnosis. When making an appointment, the patient should receive information on how the examination is performed and its estimated duration and should be questioned regarding recent iodine intake (e.g., IV contrast administration, iodine-containing drugs ...), in which cases, the indication and planning for the study should be rediscussed with the requesting physician. Patients should be informed that they may eat and drink, and of the need to report a pregnancy, any delay in the menstrual cycle, or active breastfeeding. Information leaflets and/or displays should be available in the waiting area of the nuclear medicine service, and all information should preferably be accessible through the website of the institution. The image quality and information provided by thyroid scintigraphy and RAIU are influenced by a variety of factors which can be identified and managed carefully. The percent thyroid uptake is dependent on the dietary iodine intake (which varies greatly in geographical location). The dietary iodine intake ranges from 200 to 700 µg/day and 80–500 µg/day in the USA and Europe, respectively. Continuous iodine excess intake of as little as 1 mg/day for 2 weeks will significantly diminish the radioiodine and $^{99m}\text{TcO}_4^-$ thyroidal uptake, while a single dose of 30 mg or larger will suppress thyroidal uptake to very low levels and the effect will last for days to weeks. Therefore, previous ingestion of iodine, various drugs, or use of iodinated radiocontrast agents may alter uptake and make interpretation difficult (Table 3). The thyroid uptake of other oncotropic tracers, as ^{99m}Tc -sestamibi and ^{18}F FDG, is not dependent on NIS expression and activity. Therefore, drugs and substances interfering with iodine uptake do not need to be discontinued before imaging.

Diagnostic procedures

Radiopharmaceutical activity

The activities recommended below for different tracers should be considered only a general indication, based on data in the literature and current experience (Table 4). In addition, nuclear medicine physicians in each country

Table 3 Factors that influence the thyroid uptake of iodine and iodine analogues radiopharmaceuticals and respective withdrawal time

Iodinated substances	Withdraw
Amiodarone	3 to 6 months
Intravenous contrast agents	1 to 2 months
Iodine-containing medicines and preparations	4 weeks
Iodine-containing antiseptics	4 weeks
Iodine solution (Lugol's or SSKI)	4 to 6 weeks
Oil-based-iodinated contrast agents	3 to 6 months
Kelp	4 weeks
Thyroid medications	Withdraw
Levothyroxine (LT4)	4 weeks
Liothyronine (LT3)	2 weeks
Anti-thyroid drugs (methimazole, carbimazole, PTU)	3 to 7 days
Perchlorate	1 week

should respect the diagnostic reference levels (DRLs) for radiopharmaceuticals and the rules set out in local laws. The activities administered to children should be a fraction of those administered to adults calculated in relation to body weight according to the factors given by the EANM/SNMMI Paediatric Dosage Harmonization Working Group [35, 36].

Thyroid scintigraphy with NIS-targeting radiopharmaceuticals

Instrumentation

Scintigraphic evaluation of the thyroid gland is normally performed with a conventional or small field gamma camera equipped with a parallel-hole high-resolution or a pin-hole collimator with a 15 % or 20 % window centered on the 159 KeV (^{123}I) or 140 KeV ($^{99\text{m}}\text{Tc}$) photopeak. A 128×128 or 256×256 collimator matrix size and a zoom factor of 1.5 to 2 are generally used. Notably, significant geometric distortion occurs using a pin-hole collimator and additional views with a parallel-hole collimator may be useful to search for ectopic tissue or to estimate the thyroid size.

Table 4 Thyroid radiopharmaceuticals

	$^{131}\text{I}^-$	$^{123}\text{I}^-$	$^{99\text{m}}\text{TcO}_4^-$	$^{99\text{m}}\text{Tc}$ -sestamibi	^{18}F FDG
Administration	p.o.	p.o.	i.v.	i.v.	i.v.
Activity [MBq] (adults)	0.15–0.37	7.4–14.8	74–111	185–370	200–370
Energy [KeV] (γ peak)	364	159	140	140	511 KeV
Physical half-live	8.06 days	13.2 h	6.04 h	6.04 h	110 min
Effective dose (mSv/MBq)	11	0.20	0.013	0.009	0.02 (PET) 0.04 (PET/CT)

$^{99\text{m}}\text{TcO}_4^-$, $^{99\text{m}}\text{Tc}$ -pertechnetate; i.v., intravenous; o.a., oral administration; mSV, milliSievert

Imaging protocols

Imaging is generally acquired as follows:

- At 2–6 h (early imaging) and 24 h (delayed imaging) after oral ^{123}I administration
- At 15–20 min after intravenous $^{99\text{m}}\text{TcO}_4^-$ administration
- At 10–30 min (early imaging) and 60–120 min (delayed imaging) after intravenous $^{99\text{m}}\text{Tc}$ -sestamibi administration
- At 50–70 min after intravenous ^{18}F FDG administration

Immediately prior to imaging, the patient is asked to swallow water to clear activity from mouth and esophagus. The patient is placed in a supine position, with the neck comfortably extended. It may be helpful to immobilize the head with gentle restraints. An anterior image of the neck is acquired for $100\text{--}200 \times 10^3$ counts or 5–10 min, whichever occurs first. The distance between the neck and the collimator should be minimized. The use of dedicated small field thyroid gamma camera is useful in specific cases (e.g., patients in a wheelchair, patients with severe claustrophobia). For clinical correlation of imaging findings, thyroid gland palpation can be performed at the end of image acquisition with the patient in the same position as during imaging procedure. Anatomical landmarks and palpable nodules can be identified by the placement of radioactive or radiopaque markers. A duplicate view should also be obtained without markers. The images should be appropriately labeled including the purpose of the marker when indicated (e.g. “sternal notch”). Beside an anterior image of the neck, additional oblique views and/or SPECT(-CT) acquisitions can be performed on indication, especially if substernal or ectopic thyroid is an issue. SPECT images should be acquired with a zoom between 1 and 1.3 into a 128×128 matrix. SPECT acquisition should cover a rotation of 360° (180° per detector for a dual-detector systems) with 120–128 total projections. CT should be designed to give minimal radiation dose while maintaining adequate quality for diagnosis.

Assessment of ^{123}I - thyroid uptake and kinetic (RAIU) can be obtained by using a specific gamma-probe or gamma camera (see radioiodine uptake test paragraph). A semiquantitative

evaluation of $^{99m}\text{TcO}_4^-$ uptake (TcTU) can be also obtained by measuring the syringe before and after injection and subtract counts in a background ROI from counts in a ROI drawn following the contour of the thyroid. Then, to determine the percentage of the injected dose present in the gland, the TcTU is calculated as follows:

$$\text{TcTU} = (\text{counts over thyroid-background counts}) \times 100 / \text{counts of injected activity}$$

TcTU results depend, as RAIU, on iodine intake and patient-related factors, such as the thyroid volume and, to a minor extent, the patient's age. Therefore, a local normal range should be established. [5]. Notably, in the presence of unsuppressed TSH, scintigraphic quantification of compensated autonomy is only possible if suppressible thyroid tissue has been switched off by a standardized exogenous suppression with thyroid hormones [32, 37].

Interpretation criteria and reporting

An adequate interpretation of the thyroid scintigrams requires knowledge of the current hormonal status, particularly of TSH concentration, comparison with clinical examination and, ideally, thyroid ultrasonography that provides information on the morphology of the gland, especially location, size and sonographic features of thyroid nodules. On planar scintigrams, the normal gland is butterfly-shaped and does not extend substernally. The isthmus may, or may not, be visualized and a pyramidal lobe can be recognized in about 10 % of patients. Tracer activity is normally evenly distributed throughout the thyroid gland and both salivary glands and gastric mucosa are normally visualized because they also express the NIS glycoprotein. Gray-scale documentation of the results is preferable because a discontinuous color documentation will hinder the recognition of details and may produce artifacts. The interpretation of the thyroid scan should comment on thyroid gland location, size, and morphology—radiotracer distribution throughout the gland and correlation with palpation findings and available imaging (i.e., ultrasonography). The abnormal scan may show thyroid gland enlargement, variations from the normal shape (e.g., mild thyroid gland enlargement may be suggested by the appearance of a “U-shaped” thyroid), or focal areas of increased or decreased uptake that may be single or multiple. Thyroid nodules are classified according to their ability to take up the tracer compared to that of the extranodular tissue. A hypofunctioning “cold” thyroid nodule has reduced tracer uptake, an isofunctioning “warm” nodule has tracer uptake roughly equivalent to non-nodular thyroid tissue, and a hyperfunctioning “hot” nodule has increased radiotracer uptake. The term *autonomously functioning thyroid nodule* is frequently used as synonymous for “hot” nodules

because they are characterized by their capacity to produce thyroid hormones in the absence of TSH-stimulating activity. Visualization of radiotracer uptake within a thyroglossal duct remnant and/or a pyramidal lobe is frequently seen in the setting of Graves' disease. Characterization of thyroïdal radiotracer (^{123}I - or $^{99m}\text{TcO}_4^-$) uptake as compared to that demonstrated in the salivary glands (e.g., *less than*, *equal to*, or *more than* salivary activity) may serve as a rough approximation of the overall thyroid function. However, an accurate assessment of iodine uptake and kinetics can only be obtained by performing a RAIU test (see below).

Radioiodine uptake test

Thyroid uptake determination is the measurement at selected times (e.g., 6 and 24 h and 5 days) of the fraction of an administered amount of radioactive iodine that is retained in the thyroid gland after ingestion. The percentage of radioactive iodine uptake by the thyroid usually reflects the overall function of the gland. RAIU test is performed by administering activities as little as 3.7 MBq of ^{123}I or 0.15 MBq of ^{131}I . A benefit of ^{123}I is that it allows concurrent imaging of the gland (see above).

Instrumentation

A thyroid probe is normally used and a standardized neck phantom is necessary. Alternatively, a gamma camera with a parallel-hole collimator may be used instead of a probe.

Protocols

The usual time of measurement for diagnostic purposes is 4–6 h and 24 h, and occasionally at 5 days, after radiopharmaceutical administration. Multiple measurements may be necessary for calculating the residence time and determining the ^{131}I therapeutic activity in patients with hyperthyroidism or multinodular goiter. There are several acceptable measurement and calculation techniques; the following is an example: counts are taken over the thyroid gland and the patient's mid-thigh for 1 min each at the same distance (i.e., 20–30 cm), taking care to exclude the urinary bladder from the field of view from the detector field. A source of the same radionuclide of identical activity to that given to the patient is placed in a standardized neck phantom and is counted for 1 min using the same geometry. The room background is also counted for 1 min. The RAIU is calculated using the formula:

$$\text{RAIU} = \left(\frac{\text{Patient Neck Counts} - \text{Thigh Counts}}{\text{Phantom counts} - \text{Background Counts}} \right) \times 100$$

Interpretation criteria

Normal reference ranges vary in different regions depending on iodine intake, and need to be determined locally by each nuclear medicine laboratory. RAIU test results interpretation requires knowledge of the patients' physical findings, recent thyroid function tests, and assessment of iodine and drug intake as outlined below. As an indication, any result in excess of 25 % in iodine-sufficient regions and within the setting of clinical hyperthyroidism is compatible with thyroid hyperfunction. In a small subset of hyperthyroid patients (generally affected by Graves' disease), iodine turnover is rapid that their highest thyroidal uptake is at 6–12 h; however, almost all of these patients maintain an abnormally elevated 24 h and 5 days RAIU. Elderly patients with hyperthyroidism may have a RAIU value within the normal range (commonly with toxic multinodular goiter). Low RAIU values are detected in destructive thyroiditis (injury phase): extrathyroidal source of thyroid hormone such as in the presence of ectopic thyroid tissue (e.g., struma ovarii; increased RAIU may be demonstrated at the site of ectopic tissue), exogenous thyroid hormone administration such as in *factitious thyrotoxicosis* or after iodine contamination (e.g., recent IV iodinated radiocontrast administration). Functional metastatic thyroid carcinoma and mediastinal goiter may also result in reduced RAIU values. Of note, given the dynamic events of destructive thyroiditis, it is crucial that RAIU measurements in this setting are interpreted in the light of recent thyroid function tests (e.g., within 1 week). Finally, patients with severe renal failure tend to have somewhat increased RAIU while a severe stressful illness of any kind may reduce RAIU (*euthyroid sick syndrome*).

Thyroid imaging with proliferation targeting tracers

^{99m}Tc-sestamibi scintigraphy for thyroid nodule assessment

Instrumentation and protocols

Instrumentation and image acquisition protocols are the same described for conventional thyroid scintigraphy with ^{99m}TcO₄⁻. Anterior planar images are obtained 10–30 min and 1–2 h after intravenous injection of ^{99m}Tc-sestamibi [185–370 MBq]. A SPECT or SPECT/CT can be also obtained in selected cases after reviewing planar images.

Interpretation criteria

^{99m}Tc-sestamibi images are interpreted visually and findings include a *low*, an *isointense*, or an *increased* radiotracer accumulation in the thyroid nodule in comparison to the normal thyroid tissue and in comparison to pertechnetate thyroid

scintigraphy. A “match” between pertechnetate and ^{99m}Tc-sestamibi scintigraphy is a concordantly decreased uptake in the thyroid nodule in comparison to the normal thyroid gland. A “mismatch” describes a hypofunctioning thyroid nodule on pertechnetate scintigraphy and an increased uptake of ^{99m}Tc-sestamibi in comparison to the uptake of the paranodular thyroid tissue. An “intermediate finding” describes isointense ^{99m}Tc-sestamibi uptake within the nodule in comparison to the paranodular thyroid tissue. There is some disagreement about how to read isointense ^{99m}Tc-sestamibi uptake [6, 38] and semiquantitative analysis may greatly increase diagnostic accuracy in this setting [4, 39]. For semiquantitative analysis a ROI is placed over the thyroid nodule, copied to the contralateral lobe and a background ROI is drawn on early and delayed images. The washout index (WOInd) is calculated using the formula

Washout index (WOInd)

$$= [(delayed \text{ uptake ratio} / \text{early uptake ratio}) \times 100] - 100$$

A ^{99m}Tc-sestamibi WOInd cutoff of –19 % was found to be significantly more accurate (positive likelihood ratio 4.56 for visual assessment and 12.35 for semiquantitative assessment) than mutation analysis (positive likelihood ratio 1.74) in cytologically indeterminate nodules. In particular, a negative ^{99m}Tc-sestamibi scan reliably excluded malignancy in this setting [4]. Notably, the transferability of WOInd cutoff values reported in literature should be assessed locally before its application in clinical practice. Reporting ^{99m}Tc-sestamibi thyroid imaging the following should be assessed and described in the report as appropriate: location, morphology, and size of the thyroid gland; presence of retrosternal extension; presence of diffuse tracer uptake; presence of focal tracer uptake on image corresponding or not to the US and ^{99m}TcO₄⁻ scan (i.e., cold nodule); the WOInd measurement (if calculated, see above); presence of anatomical variants or related compressive pathological conditions (e.g., tracheal deviations or vascular compressions) if concurrent SPECT/CT is performed.

¹⁸FDG PET/CT imaging for thyroid nodule assessment

Instrumentation and protocols

¹⁸FDG imaging evaluation of the thyroid gland should be acquired in the three-dimensional mode by means of a conventional system routinely used for the other oncological PET/CT examinations [40]. A non-diagnostic and low-dose CT scan is used for attenuation correction and anatomical localization of hypermetabolic foci of activity. Overall, CT parameters should be selected so as to minimize the radiation dose but to obtain the necessary diagnostic information.

Interpretation criteria

The healthy thyroid tissue is characterized by a very low ^{18}F FDG activity, allowing the identification even of small nodules with faint uptake. ^{18}F FDG PET/CT is able to identify and characterize with high accuracy small thyroid nodules (i.e., ≥ 5 mm). Indeed, the low-dose CT acquired during PET/CT may be helpful in evaluating thyroid morphology and the presence of any anatomical variant or related compressive pathological conditions (e.g., tracheal deviations or vascular compressions). Any focal uptake above normal thyroid parenchyma, corresponding to the nodule with cytological indeterminate results, is considered as positive [8]. Reporting ^{18}F FDG thyroid imaging includes location, morphology, and size of the thyroid gland: presence of retrosternal extension, presence of anatomical variants or related compressive pathological conditions (e.g., tracheal deviations or vascular compressions), presence of diffuse tracer uptake, and presence of focal tracer uptake on PET/CT image corresponding to anatomic findings on CT imaging. Maximal standardized uptake value (SUV_{max}) is a semiquantitative parameter reflecting glucose metabolic activity, but it is not a specific marker of malignancies [40]. Although many SUV_{max} thresholds have been proposed to differentiate benign from malignant lesions in patients with FDG-avid thyroid nodules incidentally detected during PET/CT examinations, no specific SUV_{max} cutoff has been identified [41, 42]. A high SUV_{max} value increases the risk of malignancy [8]; however, this finding still requires a cytological examination to confirm the diagnosis of primary thyroid malignancy.

Acknowledgments The authors thank the EANM and SNMMI committees and national delegates for their critical review of the manuscript. Also, we appreciate the great support of Sonja Niederkofler from the EANM office in Vienna and Julie Kauffman from the SNMMI office in Reston during the development of this guideline.

Compliance with ethical standards

Conflict of interest L.G. is member of Roche Diagnostics' advisory board and has received research grants and speaker honoraria from Roche Diagnostics, IBSA, and Sanofi-Genzyme. F.A.V. has received research grants from Sanofi-Genzyme and speaker honoraria from Sanofi-Genzyme, Diasorin, and Jubilant Draximage. M.L. has received research grants and speaker honoraria from Sanofi-Genzyme, Bayer, and Astra Zeneca. Other authors declare that they have no conflicts of interest. E.W. states that the opinions and assertions expressed herein are his own opinions and do not necessarily reflect the official policy or position of the Department of Defense or the Department of Air Force of the USA.

Ethical approval This article does not contain any studies with human participants or animals performed by any of the authors.


References

- Baker CH, Morris JC. The sodium-iodide symporter. *Curr Drug Targets Immune Endocr Metabol Disord*. 2004;4:167–74.
- Dohan O, De la Vieja A, Paroder V, Riedel C, Artani M, Reed M, et al. The sodium/iodide symporter (NIS): characterization, regulation, and medical significance. *Endocr Rev*. 2003;24:48–77.
- Giovanella L, Ceriani L, Treglia G. Role of isotope scan, including positron emission tomography/computed tomography, in nodular goitre. *Best Pract Res Clin Endocrinol Metab*. 2014;28:507–18.
- Giovanella L, Campenni A, Treglia G, Verburg FA, Trimboli P, Ceriani L, et al. Molecular imaging with (99m)Tc-MIBI and molecular testing for mutations in differentiating benign from malignant follicular neoplasm: a prospective comparison. *Eur J Nucl Med Mol Imaging*. 2016;43:1018–26.
- Treglia G, Caldarella C, Saggiorato E, Ceriani L, Orlandi F, Salvatori M, et al. Diagnostic performance of (99m)Tc-MIBI scan in predicting the malignancy of thyroid nodules: a meta-analysis. *Endocrine*. 2013;44:70–8.
- Theissen P, Schmidt M, Ivanova T, Dietlein M, Schicha H. MIBI scintigraphy in hypofunctioning thyroid nodules—can it predict the dignity of the lesion? *Nuklearmedizin*. 2009;48:144–52.
- Treglia G, Bertagna F, Sadeghi R, Verburg FA, Ceriani L, Giovanella L. Focal thyroid incidental uptake detected by ^{18}F -fluorodeoxyglucose positron emission tomography. *Nuklearmedizin*. 2013;52(04):130–6.
- Piccardo A, Puntoni M, Bertagna F, Treglia G, Foppiani L, Arecco F, et al. (18)F-FDG uptake as a prognostic variable in primary differentiated thyroid cancer incidentally detected by PET/CT: a multicentre study. *Eur J Nucl Med Mol Imaging*. 2014;41:1482–91.
- Kusic Z, Becker DV, Saenger EL, Paras P, Gartside P, Wessler T, et al. Comparison of technetium-99m and iodine-123 imaging of thyroid nodules: correlation with pathologic findings. *J Nucl Med*. 1990;31:393–9.
- Bongiovanni MPG, Ceriani L, Pusztaszeri M. Cellular and molecular basis for thyroid cancer imaging in nuclear medicine. *Clin Transl Imaging*. 2013;1:149–61.
- Silberstein EB, Alavi A, Balon HR, Clarke SEM, Divgi C, Gelfand MJ, et al. The SNM practice guideline for therapy of thyroid disease with ^{131}I 3.0*. *J Nucl Med*. 2012;53:1633–51.
- Hanscheid H, Canzi C, Eschner W, Flux G, Luster M, Strigari L, et al. EANM Dosimetry Committee series on standard operational procedures for pre-therapeutic dosimetry II. Dosimetry prior to radioiodine therapy of benign thyroid diseases. *Eur J Nucl Med Mol Imaging*. 2013;40:1126–34.
- Piga M, Cocco MC, Serra A, Boi F, Loy M, Mariotti S. The usefulness of $^{99\text{m}}\text{Tc}$ -sestaMIBI thyroid scan in the differential diagnosis and management of amiodarone-induced thyrotoxicosis. *Eur J Endocrinol*. 2008;159(4):423–9.
- Pattison DA, Westcott J, Lichtenstein M, Toh HB, Gunawardana D, Better N, et al. Quantitative assessment of thyroid-to-background ratio improves the interobserver reliability of technetium-99m sestamibi thyroid scintigraphy for investigation of amiodarone-induced thyrotoxicosis. *Nucl Med Commun*. 2015;36(4):356–62.
- Tessler FN, Middleton WD, Grant EG, Hoang JK, Berland LL, Teefey SA, et al. ACR thyroid imaging, reporting and data system (TI-RADS): white paper of the ACR TI-RADS committee. *J Am Coll Radiol*. 2017;14(5):587–95.
- Schroder S, Marthaler B. Autonomy and malignancy of thyroid gland tumors. A critical analysis of the literature on the existence of hyperfunctioning follicular and papillary thyroid gland carcinomas. *Pathologie*. 1996;17(5):349–57.
- Lupi A, Orsolon P, Cerisara D, Deantoni Migliorati G, Vianello Dri A. “Hot” carcinoma of the thyroid. Case reports and comments on the literature. *Minerva Endocrinol*. 2002;27(1):53–7.
- Schenke S, Seifert P, Zimny M, Winkens T, Binse I, Goerges R. Risk stratification of thyroid nodules using Thyroid Imaging Reporting and Data System (TIRADS): the omission of thyroid

- scintigraphy increases the rate of falsely suspected lesions. *J Nucl Med*. 2018.
19. Giovanella L, D'Aurizio F, Campenni A, Ruggeri RM, Baldari S, Verburg FA, et al. Searching for the most effective thyrotropin (TSH) threshold to rule-out autonomously functioning thyroid nodules in iodine deficient regions. *Endocrine*. 2016;54(3):757–61.
 20. Haugen BR, Alexander EK, Bible KC, Doherty GM, Mandel SJ, Nikiforov YE, et al. 2015 American Thyroid Association management guidelines for adult patients with thyroid nodules and differentiated thyroid cancer: the American Thyroid Association guidelines Task Force on thyroid nodules and differentiated thyroid cancer. *Thyroid*. 2016;26:1–133.
 21. Musholt TJ, Clerici T, Dralle H, Frilling A, Goretzki PE, Hermann MM, et al. German Association of Endocrine Surgeons practice guidelines for the surgical treatment of benign thyroid disease. *Langenbeck's Arch Surg*. 2011;396:639–49.
 22. Gharib H, Papini E, Paschke R, Duick DS, Valcavi R, Hegedus L, et al. American Association of Clinical Endocrinologists, Associazione Medici Endocrinologi, and European Thyroid Association medical guidelines for clinical practice for the diagnosis and management of thyroid nodules. *Endocr Pract*. 2010;16(Suppl 1):1–43.
 23. Grant EG, Tessler FN, Hoang JK, Langer JE, Beland MD, Berland LL, et al. Thyroid ultrasound reporting lexicon: white paper of the ACR thyroid imaging, reporting and data system (TIRADS) committee. *J Am Coll Radiol*. 2015;12:1272–9.
 24. Cibas ES, Ali SZ. The 2017 Bethesda system for reporting thyroid cytopathology. *Thyroid*. 2017;27:1341–6.
 25. Ross D. Evaluation and management of thyroid nodules with indeterminate cytology. Up to date. 2018. <https://uptodate.com>. Accessed Jan 6 2019
 26. Alexander EK, Kennedy GC, Baloch ZW, Cibas ES, Chudova D, Diggans J, et al. Preoperative diagnosis of benign thyroid nodules with indeterminate cytology. *N Engl J Med*. 2012;367:705–15.
 27. Alexander EK, Schorr M, Klopper J, Kim C, Sipos J, Nabhan F, et al. Multicenter clinical experience with the Afirma gene expression classifier. *J Clin Endocrinol Metab*. 2014;99:119–25.
 28. Are C, Hsu JF, Ghossein RA, Schoder H, Shah JP, Saha AR. Histological aggressiveness of fluorodeoxyglucose positron-emission tomography (FDG-PET)-detected incidental thyroid carcinomas. *Ann Surg Oncol*. 2007;14:3210–5.
 29. de Koster EJ, de Geus-Oei LF, Dekkers OM, van Engen-van Grunsven I, Hamming J, Corssmit EPM, et al. Diagnostic utility of molecular and imaging biomarkers in cytological indeterminate thyroid nodules. *Endocr Rev*. 2018;39:154–91.
 30. Klett M. Epidemiology of congenital hypothyroidism. *Exp Clin Endocrinol Diabetes*. 1997;105(Suppl 4):19–23.
 31. Clerc J, Monpeyssen H, Chevalier A, Amegassi F, Rodrigue D, Leger FA, et al. Scintigraphic imaging of paediatric thyroid dysfunction. *Horm Res*. 2008;70:1–13.
 32. Meller J, Becker W. The continuing importance of thyroid scintigraphy in the era of high-resolution ultrasound. *Eur J Nucl Med Mol Imaging*. 2002;29(Suppl 2): 425–38.
 33. Keller-Petrot I, Leger J, Sergent-Alaoui A, de Labriolle-Vaylet C. Congenital hypothyroidism: role of nuclear medicine. *Semin Nucl Med*. 2017;47:135–42.
 34. ACR Practice Guidelines for Imaging Pregnant or Potentially Pregnant Adolescents and Women With Ionizing Radiation 2008 [Available from: <https://www.acr.org/-/media/ACR/Files/Practice-Parameters/Pregnant-Pts.pdf?la=en>. Accessed May 30th, 2019).
 35. Lassmann M, Treves ST. Pediatric radiopharmaceutical administration: harmonization of the 2007 EANM Paediatric dosage card (version 1.5.2008) and the 2010 North American consensus guideline. *Eur J Nucl Med Mol Imaging*. 2014;41:1636–041.
 36. Gelfand MJ, Clements C, MacLean JR. Nuclear medicine procedures in children: special considerations. *Semin Nucl Med*. 2017;47:110–7.
 37. Shimmins J, Alexander WD, McLarty DG, Robertson JW, Sloane DJ. ^{99m}Tc-pertechnetate for measuring thyroid suppressibility. *J Nucl Med*. 1971;12:51–4.
 38. Hurtado-Lopez LM, Martinez-Duncker C. Negative MIBI thyroid scans exclude differentiated and medullary thyroid cancer in 100% of patients with hypofunctioning thyroid nodules. *Eur J Nucl Med Mol Imaging*. 2007;34:1701–3.
 39. Campenni A, Siracusa M, Ruggeri RM, Laudicella R, Pignata SA, Baldari S, et al. Differentiating malignant from benign thyroid nodules with indeterminate cytology by (^{99m}Tc)-MIBI scan: a new quantitative method for improving diagnostic accuracy. *Sci Rep*. 2017;7:6147.
 40. Merten MM, Castro MR, Zhang J, Durski J, Ryder M. Examining the role of preoperative positron emission tomography/computerized tomography in combination with ultrasonography in discriminating benign from malignant cytologically indeterminate thyroid nodules. *Thyroid*. 2017;27:95–102.
 41. Pak K, Kim SJ, Kim IJ, Kim BH, Kim SS, Jeon YK. The role of ¹⁸F-fluorodeoxyglucose positron emission tomography in differentiated thyroid cancer before surgery. *Endocr Relat Cancer*. 2013;20: 203–13.
 42. Piccardo A, Puntoni M, Treglia G, Foppiani L, Bertagna F, Paparo F, et al. Thyroid nodules with indeterminate cytology: prospective comparison between ¹⁸F-FDG-PET/CT, multiparametric neck ultrasonography, ^{99m}Tc-MIBI scintigraphy and histology. *Eur J Endocrinol*. 2016;174:693–703.

Publisher's note Springer Nature remains neutral with regard to jurisdictional claims in published maps and institutional affiliations.

Affiliations

Luca Giovanella^{1,2}  · Anca M. Avram³ · Ioannis Iakovou⁴ · Jennifer Kwak⁵ · Susan A. Lawson³ · Elizabeth Lulaj⁶ · Markus Luster⁷ · Arnoldo Piccardo⁸ · Matthias Schmidt⁹ · Mark Tulchinsky¹⁰ · Frederick A. Verburg⁷ · Ely Wolin¹¹

¹ Clinic for Nuclear Medicine and Thyroid Competence Center, Imaging Institute of Southern Switzerland, Ente Ospedaliero Cantonale, Via Ospedale 6, CH-6500 Bellinzona, Switzerland

² Clinic for Nuclear Medicine, University Hospital and University of Zurich, Zurich, Switzerland

³ Division of Nuclear Medicine, Department of Radiology, University of Michigan, Ann Arbor, MI, USA

⁴ Department of Nuclear Medicine, Papageorgiou Hospital, Aristotle University, Thessaloniki, Greece

⁵ Division of Nuclear Medicine, Department of Radiology, University of Colorado, Denver, CO, USA

- ⁶ Division of Nuclear Medicine, Department of Radiology, Johns Hopkins Medical Institute, Baltimore, MD, USA
- ⁷ Clinic for Nuclear Medicine, Marburg University Hospital, Marburg, Germany
- ⁸ Nuclear Medicine Unit, Imaging Department, Ente Ospedaliero Ospedali Galliera, Genoa, Italy
- ⁹ Clinic for Nuclear Medicine, Cologne University Hospital, Cologne, Germany
- ¹⁰ Division of Nuclear Medicine, Department of Radiology, Penn State University, Hershey, PA, USA
- ¹¹ Division of Nuclear Medicine, Department of Radiology, David Grant Medical Center, Vacaville, CA, USA