

ACR Thyroid Imaging, Reporting and Data System (TI-RADS): White Paper of the ACR TI-RADS Committee

Franklin N. Tessler, MD, CM^a, William D. Middleton, MD^b, Edward G. Grant, MD^c, Jenny K. Hoang, MBBS^d, Lincoln L. Berland, MD^a, Sharlene A. Teefey, MD^b, John J. Cronan, MD^e, Michael D. Beland, MD^e, Terry S. Desser, MD^f, Mary C. Frates, MD^g, Lynwood W. Hammers, DO^{h,i}, Ulrike M. Hamper, MD^j, Jill E. Langer, MD^k, Carl C. Reading, MD^l, Leslie M. Scoutt, MD^m, A. Thomas Stavros, MDⁿ

Abstract

Thyroid nodules are a frequent finding on neck sonography. Most nodules are benign; therefore, many nodules are biopsied to identify the small number that are malignant or require surgery for a definitive diagnosis. Since 2009, many professional societies and investigators have proposed ultrasound-based risk stratification systems to identify nodules that warrant biopsy or sonographic follow-up. Because some of these systems were founded on the BI-RADS[®] classification that is widely used in breast imaging, their authors chose to apply the acronym TI-RADS, for Thyroid Imaging, Reporting and Data System. In 2012, the ACR convened committees to (1) provide recommendations for reporting incidental thyroid nodules, (2) develop a set of standard terms (lexicon) for ultrasound reporting, and (3) propose a TI-RADS on the basis of the lexicon. The committees published the results of the first two efforts in 2015. In this article, the authors present the ACR TI-RADS Committee's recommendations, which provide guidance regarding management of thyroid nodules on the basis of their ultrasound appearance. The authors also describe the committee's future directions.

Key Words: Thyroid nodule, thyroid cancer, management guidelines, ultrasound

J Am Coll Radiol 2017;■:■-■. Copyright © 2017 American College of Radiology

INTRODUCTION

Thyroid nodules are exceedingly common, with a reported prevalence of up to 68% in adults on high-resolution ultrasound [1]. Currently, fine-needle aspiration (FNA)

is the most effective, practical test to determine whether a nodule is malignant or may require surgery to reach a definitive diagnosis [2]. However, most nodules are benign, and even malignant nodules, particularly ones

^aDepartment of Radiology, University of Alabama at Birmingham, Birmingham, Alabama.

^bMallinckrodt Institute of Radiology, Washington University School of Medicine, St Louis, Missouri.

^cDepartment of Radiology, Keck School of Medicine, University of Southern California, Los Angeles, California.

^dDepartment of Radiology, Duke University School of Medicine, Durham, North Carolina.

^eDepartment of Diagnostic Imaging Brown University, Providence, Rhode Island.

^fDepartment of Radiology, Stanford University Medical Center, Stanford, California.

^gDepartment of Radiology, Brigham and Women's Hospital, Boston, Massachusetts.

^hHammers Healthcare Imaging, New Haven, Connecticut.

ⁱDepartment of Internal Medicine, Yale School of Medicine, New Haven, Connecticut.

^jDepartment of Radiology and Radiological Science, Johns Hopkins University, School of Medicine, Baltimore, Maryland.

^kDepartment of Radiology, University of Pennsylvania, Philadelphia, Pennsylvania.

^lDepartment of Radiology, Mayo Clinic College of Medicine, Rochester, Minnesota.

^mDepartment of Radiology and Biomedical Imaging, Yale University, New Haven, Connecticut.

ⁿDepartment of Radiology, University of Texas Health Sciences Center, San Antonio, Texas.

Corresponding author and reprints: Franklin N. Tessler, MD, CM, Department of Radiology, University of Alabama at Birmingham, Birmingham, AL 35249; e-mail: fessler@uabmc.edu.

Dr Berland received personal fees from Nuance Communications during the conduct of the study. Dr Beland has received personal fees from Hitachi Aloka America outside the submitted work. All other authors have no conflicts of interest related to the material discussed in this article.

smaller than 1 cm, frequently exhibit indolent or nonaggressive behavior [3-5]. Therefore, not all detected nodules require FNA and/or surgery.

Despite a rapid increase in the reported incidence of papillary thyroid cancer that resulted from screening thyroid sonography in asymptomatic patients in South Korea, mortality has remained extremely low [6]. In the United States, overdiagnosis of thyroid cancer, defined as “diagnosis of thyroid tumors that would not, if left alone, result in symptoms or death” accounted for 70% to 80% of thyroid cancer cases in women and 45% of cases in men between 2003 and 2007 [7].

Therefore, a reliable, noninvasive method to identify which nodules warrant FNA on the basis of a reasonable likelihood of biologically significant malignancy would be highly desirable. In 2015, committees convened by the ACR published white papers that presented an approach to incidental thyroid nodules and proposed standard terminology (lexicon) for ultrasound reporting [8,9]. The purpose of the present white paper is to present our system for risk stratification, which is designed to identify most clinically significant malignancies while reducing the number of biopsies performed on benign nodules.

PROJECT RATIONALE AND CONSENSUS PROCESS

Several professional societies and groups of investigators have proposed methods to guide ultrasound practitioners in recommending FNA on the basis of ultrasound features [10-18]. Some of these systems were termed TI-RADS (Thyroid Imaging, Reporting and Data System) because they were modeled on the ACR’s BI-RADS[®], which has been widely accepted in breast imaging. Other societies, such as the American Thyroid Association (ATA), have taken a slightly different, pattern-oriented approach, but with the same intent [19]. The plethora, complexity, and lack of congruence of these systems has limited their adoption by the ultrasound community and inspired our effort to publish a classification system under the auspices of the ACR. The ACR TI-RADS Committee agreed on the following attributes for our risk classification algorithm. It would be:

- founded on the ultrasound features defined in our previously published lexicon;
- easy to apply across a wide gamut of ultrasound practices;
- able to classify all thyroid nodules; and
- evidence based to the greatest extent possible.

The proposals presented in this white paper, which were developed via conference calls, e-mail, and online

surveys, represent the consensus opinion of the ACR TI-RADS Committee. They are based on the literature; analysis of data from the Surveillance, Epidemiology, and End Results (SEER) Program of the National Cancer Institute; evaluation of existing risk classification systems; and expert opinion. Our recommendations are intended to serve as guidance for practitioners who incorporate ultrasound in the management of adult patients with thyroid nodules. They should not be construed as standards. Interpreting and referring physicians are legally and professionally responsible for applying their professional judgment to every case, regardless of the ACR TI-RADS recommendations. The decision to perform FNA should also account for the referring physician’s preference and the patient’s risk factors for thyroid cancer, anxiety, comorbidities, life expectancy, and other relevant considerations.

OVERVIEW OF ACR TI-RADS

The ultrasound features in the ACR TI-RADS are categorized as benign, minimally suspicious, moderately suspicious, or highly suspicious for malignancy. Points are given for all the ultrasound features in a nodule, with more suspicious features being awarded additional points. [Figure 1](#) presents these features arranged per the five lexicon categories [8]. When assessing a nodule, the reader selects one feature from each of the first four categories and all the features that apply from the final category and sums the points. The point total determines the nodule’s ACR TI-RADS level, which ranges from TR1 (benign) to TR5 (high suspicion of malignancy). Note that although it is possible for a nodule to be awarded zero points and hence be characterized as TR1, all other nodules merit at least two points because a nodule that has a mixed cystic and solid composition (one point) will also gain at least one more point for the echogenicity of its solid component. Finally, although sonoelastography is a promising technique [20,21], it is probably not available in many ultrasound laboratories and is not incorporated into the ACR TI-RADS.

In the ACR TI-RADS, recommendations for FNA or ultrasound follow-up are based on a nodule’s ACR TI-RADS level and its maximum diameter. For risk levels TR3 through TR5, the chart presents a size threshold at or above which FNA should be recommended. We also defined lower size limits for recommending follow-up ultrasound for TR3, TR4, and TR5 nodules to limit the number of repeat sonograms for those that are likely to be benign or not clinically significant.

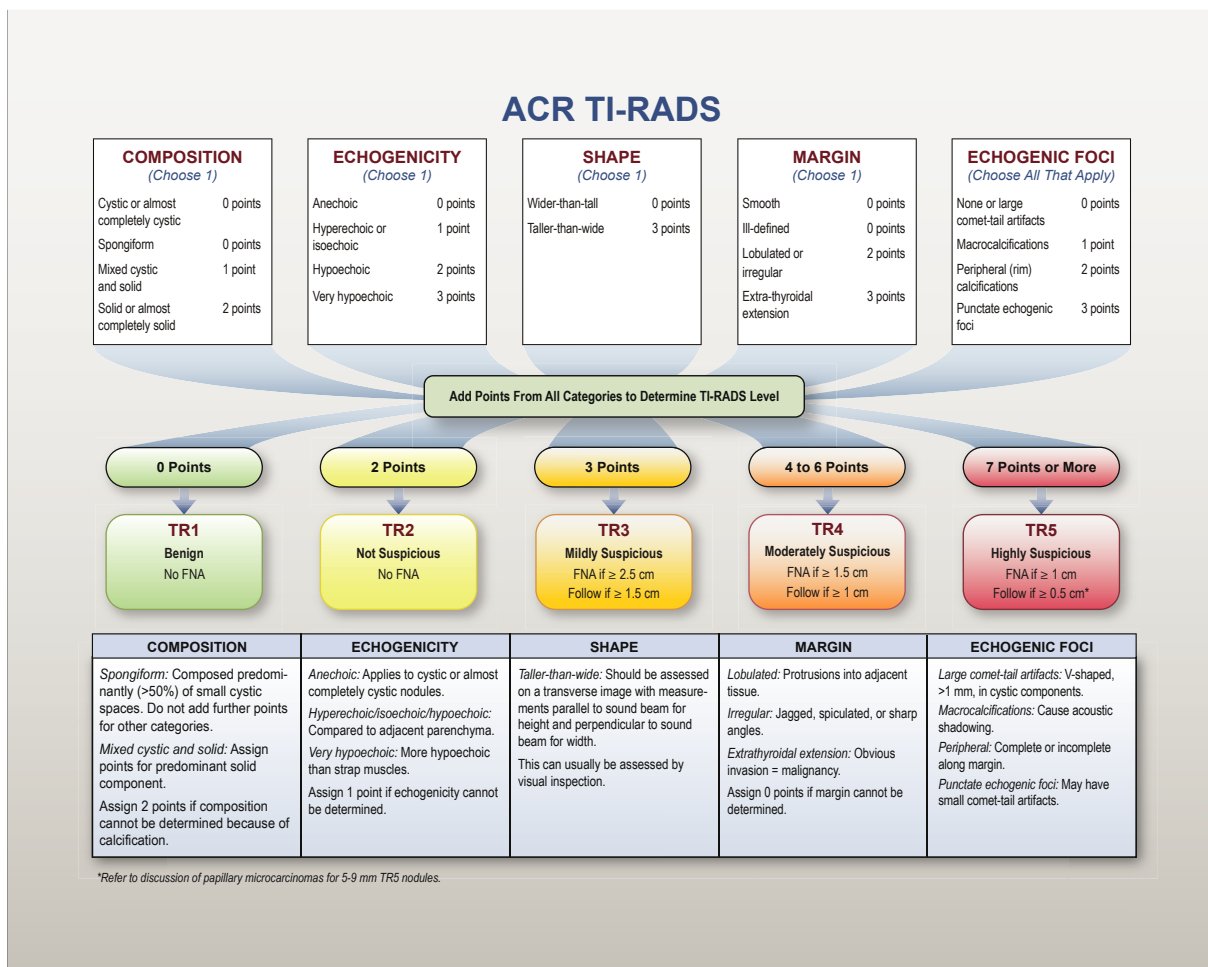


Fig 1. Chart showing five categories on the basis of the ACR Thyroid Imaging, Reporting and Data System (TI-RADS) lexicon, TR levels, and criteria for fine-needle aspiration or follow-up ultrasound. Explanatory notes appear at the bottom.

In developing the ACR TI-RADS, the committee strived to account for the discrepancy between the sharp rise in the diagnosis and treatment of thyroid cancer resulting from increased detection and biopsy and the lack of commensurate improvement in long-term outcomes [22]. This suggested to us that diagnosing every thyroid malignancy should not be our goal. Like other professional societies [17,19], we recommend biopsy of high-suspicion nodules only if they are 1 cm or larger. As well, we advocate biopsy of nodules that have a low risk for malignancy only when they measure 2.5 cm or more.

The ACR TI-RADS is designed to balance the benefit of identifying clinically important cancers against the risk and cost of subjecting patients with benign nodules or indolent cancers to biopsy and treatment. Our recommendations for follow-up ultrasound substantially mitigate the possibility that significant malignancies will remain undetected over time and are concordant with the

increasing trend toward active surveillance (“watchful waiting”) for low-risk thyroid cancer [23,24].

DIFFERENCES BETWEEN ACR TI-RADS AND OTHER SYSTEMS

Structure

To make the system easy to understand and apply, the ACR TI-RADS does not include subcategories, nor does it include a TR0 category to indicate a normal thyroid gland. The ACR TI-RADS also lends itself to implementation as templates in voice recognition reporting or computerized decision support systems. The committee decided against the pattern-based approach used by the ATA on the basis of the results of a study by Yoon et al [25], which showed that the ATA guidelines were unable to classify 3.4% of 1,293 nodules, of which 18.2% were malignant. Notably, that study included only nodules that were subjected to FNA or surgery. It is likely that

an even greater percentage of nodules would not have been categorized had other nodules been included, as it is not practical to provide patterns that account for every potential constellation of features.

Size Thresholds for FNA

The ACR TI-RADS is consistent with most other guidelines in recommending FNA for highly suspicious nodules 1 cm or larger. However, our thresholds for mildly suspicious and moderately suspicious nodules (2.5 and 1.5 cm, respectively) are higher than the cutoffs advocated by the ATA and the Korean Society of Thyroid Radiology [17,19].

In a 2005 publication cited by both organizations, Machens et al [26] contended that the cumulative risk for distant metastases from papillary and follicular thyroid cancer rose at a threshold of 2 cm. They therefore advocated biopsy of nodules larger than 2 cm. However, our review of their graphs suggested a gradual, slight increase that began at a larger size. More important, Machens et al based their analysis on tumor size in resected specimens, not on ultrasound dimensions. Subsequent research has demonstrated a significant lack of concordance between sonographic and pathologic sizing, with a tendency for ultrasound to result in larger measurements [27]. Of 205 papillary carcinomas ≥ 1.5 cm studied by Bachar et al [28], the mean diameter on ultrasound was 2.65 ± 1.07 cm, compared with 1.97 ± 1.17 cm on pathology. The committee's higher size cutoffs reflect this discrepancy.

Our choices were further guided by evaluation of a database of more than 3,000 proven thyroid nodules that was created for a study sponsored by the Society of Radiologists in Ultrasound [29]. Partial analysis showed cancer risk levels of no more than 2% for TR1 and TR2 nodules, 5% for TR3 nodules, 5% to 20% for TR4 nodules, and at least 20% for TR5 nodules. We also considered published [30] and newly performed SEER data analyses that showed a slight increase in distant metastases at 2.5 cm, as well as slight increments in 10-year relative and thyroid cancer-specific mortality at 3 cm.

ACR TI-RADS FEATURE CATEGORIES

In this section, we elaborate on the five groups of ultrasound findings, ACR TI-RADS levels, and size thresholds. Readers are encouraged to refer to the lexicon white paper for detailed descriptions of all the categories and features [8]. As well, any history of prior FNA or ethanol ablation should be sought, as these procedures may lead to a suspicious appearance at follow-up ultrasound [31].

Composition

Nodules that are cystic or almost completely cystic merit no points because they are almost universally benign [16]. Similarly, a spongiform architecture is highly correlated with benign cytology, regardless of its relative echogenicity or other features [32-34]. However, a spongiform nodule must be composed predominantly (>50%) of small cystic spaces [8]. Nodules should not be characterized as spongiform solely on the basis of the presence of a few, scattered cystic components in an otherwise solid nodule (Online Fig. 2).

"Mixed cystic and solid" combines two features from the lexicon, predominately solid and predominately cystic. The appearance of the solid component is more important than the overall size of the nodule or the proportion of solid versus cystic components in determining whether biopsy is warranted. Solid material that is eccentric and has an acute angle with the nodule's wall is suspicious, as is solid material with moderately or highly suspicious characteristics, such as decreased echogenicity, lobulation, and punctate echogenic foci [35-38]. As well, although color Doppler ultrasound has not been shown to reliably discriminate between benign and malignant nodules [39], the presence of flow in solid components distinguishes tissue from echogenic debris or hemorrhage. Inconsequential debris may be identified by layering or motion elicited by changes in patient position.

Echogenicity

This feature refers to a nodule's reflectivity relative to adjacent thyroid tissue, except for very hypoechoic nodules, in which the strap muscles are used as the basis for comparison. This category also includes "anechoic," a zero-point feature that was absent from the lexicon. It applies to cystic or almost completely cystic nodules that would otherwise be given three points because of their very hypoechoic appearance.

Shape

A taller-than-wide shape is an insensitive but highly specific indicator of malignancy [12,13,40]. This feature is evaluated in the axial plane by comparing the height ("tallness") and width of a nodule measured parallel and perpendicular to the ultrasound beam, respectively. A taller-than-wide configuration is usually evident on visual inspection and rarely requires formal measurements.

Margin

The presence of a halo is neither discriminatory nor mutually exclusive with other margin types; therefore, we

ected to omit it. We included “ill defined” in this group so that any reporting template that incorporates a field for margin will not be left empty if a nodule is not well defined. “Lobulated or irregular margin” refers to a spiculated or jagged edge, with or without protrusions into the surrounding parenchyma. It may be difficult to recognize this finding if the nodule is ill defined, is embedded in a heterogeneous gland, or abuts multiple other nodules. If the margin cannot be determined for any reason, zero points should be assigned.

Extension beyond the thyroid border is classified as extensive or minimal [41]. (We use the term *border* because the thyroid gland lacks a true fibrous capsule [42].) Extensive extrathyroidal extension (ETE) that is characterized by frank invasion of adjacent soft tissue and/or vascular structures is a highly reliable sign of malignancy and is an unfavorable prognostic sign [43]. Minimal ETE may be suspected sonographically in the presence of border abutment, contour bulging, or loss of the echogenic thyroid border [44,45]. However, agreement among pathologists for identification of minimal ETE is poor [46], and its clinical significance is controversial [41,47,48]. Therefore, practitioners should exercise caution when reporting minimal ETE, particularly for otherwise benign-appearing nodules.

Echogenic Foci

“Large comet-tail artifacts” are echogenic foci with V-shaped echoes >1 mm deep to them. They are associated with colloid and are strongly indicative of benignity when found within the cystic components of thyroid nodules. “Macrocalcifications” are coarse echogenic foci accompanied by acoustic shadowing. Evidence in the literature regarding their association with increased malignancy risk is mixed, especially in nodules lacking other malignant features [12,49-51]. Given published data that show a weakly positive relationship with malignancy [52], macrocalcifications are assigned one point, recognizing that the risk is increased if the nodule also contains moderately or highly suspicious features that warrant additional points.

Peripheral calcifications lie along all or part of a nodule’s margin. Their correlation with malignancy in the literature is variable [49]. However, because some publications suggest that they are more strongly associated with malignancy than macrocalcifications, they are awarded two points [52]. Some authors have called attention to interrupted peripheral calcifications with protruding soft tissue as suspicious for malignancy, but with low specificity [53]. In the ACR TI-RADS, this appearance qualifies as a lobulated margin, which

adds another two points to the nodule’s total assignment. In nodules with calcifications that cause strong acoustic shadowing that precludes or limits assessment of internal characteristics, particularly echogenicity and composition, it is best to assume that the nodule is solid and assign two points for composition and one point for echogenicity.

Punctate echogenic foci are smaller than macrocalcifications and are nonshadowing. In the solid components of thyroid nodules, they may correspond to the psammomatous calcifications associated with papillary cancers and are therefore considered highly suspicious, particularly in combination with other suspicious features. This category includes echogenic foci that are associated with small comet-tail artifacts in solid components, as distinguished from the large comet-tail artifacts described earlier [54]. Notably, small echogenic foci may be seen in spongiform nodules, where they probably represent the back walls of minute cysts. They are not suspicious in this circumstance and should not add to the point total of spongiform nodules.

Additional Benign Appearances

Several ultrasound findings have been described as characteristic of benign nodules with a high degree of reliability. These include a uniformly hyperechoic (“white knight”) appearance, as well as a variegated pattern of hyperechoic areas separated by hypoechoic bands reminiscent of giraffe hide, both in the setting of Hashimoto’s thyroiditis [34]. Because of their scarcity, the committee chose not to formally incorporate these patterns in the ACR TI-RADS chart.

PAPILLARY THYROID MICROCARCINOMAS

The ACR TI-RADS is concordant with other guidelines in recommending against routine biopsy of nodules smaller than 1 cm, even if they are highly suspicious. However, because some thyroid specialists advocate active surveillance, ablation, or lobectomy for papillary microcarcinomas, biopsy of 5- to 9-mm TR5 nodules may be appropriate under certain circumstances [24,55-57]. The determination to perform FNA will involve shared decision making between the referring physician and the patient. The report should indicate whether the nodule can be measured reproducibly on follow-up studies. Additionally, nodules in critical submarginal locations may complicate surgery [24,55,56]. Therefore, the report should also indicate whether the nodule abuts the trachea or whether it is adjacent to the tracheoesophageal groove (the location of the recurrent laryngeal nerve).

REPORTING CONSIDERATIONS

Measurement and Documentation

Accurate sizing of thyroid nodules is critical, as the maximum dimension determines whether a given lesion should be biopsied or followed. Although some interobserver discrepancy is inevitable because of variable conspicuity, consistent technique improves measurement accuracy and reproducibility.

Nodules should be measured in three axes: (1) maximum dimension on an axial image, (2) maximum dimension perpendicular to the previous measurement on the same image, and (3) maximum longitudinal dimension on a sagittal image (Online Fig. 3) [58]. For obliquely oriented nodules, these measurements may be different than the ones used to determine a taller-than-wide shape, but this discrepancy should rarely present a problem in practice. Measurements should also include the nodule's halo, if present. Practitioners may use linear dimensions to determine volume, a calculation that is available on many ultrasound machines. Regardless of the method used, each practice should measure and report nodules consistently to facilitate serial comparison.

Meticulous documentation of the location of nodules on sonograms is equally important, particularly when the thyroid gland is heterogeneous or multiple nodules are present. Every nodule targeted for surveillance should be numbered sequentially and labeled as to its location in the thyroid gland (right, left, isthmus, upper, mid, lower, and, if necessary, lateral, medial, anterior, or posterior). Ultrasound video clips are valuable to provide further information about the spatial relationships between nodules and adjacent structures. The committee recommends that no more than four nodules with the highest ACR TI-RADS point scores that fall below the size threshold for FNA should be followed, as detailed reporting of more than four nodules would needlessly complicate and lengthen reports. Other nodules may be reassessed on subsequent sonograms without being formally enumerated.

The committee did not address follow-up for previously sampled nodules. The decision to request a repeat biopsy is typically driven by referring physicians and is guided by management recommendations based on prior FNA results based on the Bethesda System for Reporting Thyroid Cytopathology [19,59,60].

Definition of Growth

Criteria for significant growth depend on the size of the nodule and must take measurement variability into

account. In the ACR TI-RADS, significant enlargement is defined as a 20% increase in at least two nodule dimensions and a minimal increase of 2 mm, or a 50% or greater increase in volume, as in the criteria adopted by other professional societies [19]. Because enlargement may not be apparent if the current sonogram is compared only with the immediately preceding one, it is important to also review measurements from earlier scans, if available.

Timing of Follow-Up Sonograms

There is little consensus in the literature regarding optimal spacing of follow-up sonograms for nodules that do not meet size criteria for FNA, as growth rates do not reliably distinguish benign from malignant nodules [61]. The committee believes that scanning intervals of less than 1 year are not warranted [62], except for proven cancers under active surveillance, which may require more frequent follow-up at the discretion of the referring physician [56]. We advocate timing on the basis of a nodule's ACR TI-RADS level, with additional sonograms for lesions that are more suspicious. For a TR5 lesion, we recommend scans every year for up to 5 years. For a TR4 lesion, scans should be done at 1, 2, 3, and 5 years. For a TR3 lesion, follow-up imaging may be performed at 1, 3, and 5 years. Imaging can stop at 5 years if there is no change in size, as stability over that time span reliably indicates that a nodule has a benign behavior [63]. There is no published evidence to guide management of nodules that enlarge significantly but remain below the FNA size threshold for their ACR TI-RADS level at 5 years, but continued follow-up is probably warranted. If a nodule's ACR TI-RADS level increases on follow-up, the next sonogram should be done in 1 year, regardless of its initial level.

Number of Nodules to Biopsy

Biopsy of three or more nodules is poorly tolerated by patients and increases cost with little or no benefit and some added risk. Therefore, the committee recommends targeting no more than two nodules with the highest ACR TI-RADS point totals that meet criteria for FNA. Size should not be the primary criterion for deciding which nodule(s) to sample. We discourage usage of the term *dominant nodule*, which is often applied to the largest lesion in the gland, because it downplays the primary role of architecture in determining management. If three or more nodules fall within ACR TI-RADS guidelines for biopsy, the two with the most suspicious appearance on the basis of point totals should be

biopsied, even if they are not the largest. Conversely, in a gland that contains multiple discrete nodules that do not meet criteria, there is little reason to subject the largest one to FNA solely because of its size. Although malignancy cannot be definitively excluded under these conditions, sampling variation lessens the chance of detecting cancer because it would be impractical to biopsy every nodule. Likewise, biopsy is usually not indicated in a gland that is replaced by multiple, confluent nodules of similar appearance.

Assessment of Cervical Lymph Nodes

Evaluation of cervical lymph nodes is a vital part of every thyroid sonographic examination [64]. Abnormal findings suggestive of cervical lymph node metastasis include a globular shape, loss of the normal echogenic hilum, presence of peripheral rather than hilar flow, heterogeneity with cystic components, and punctate echogenic foci that may represent microcalcifications. Detailed discussions of these features and representative ultrasound images are available elsewhere [65-67]. We recommend FNA of suspicious nodes, in addition to up to two nodules that warrant biopsy on the basis of the ACR TI-RADS.

FUTURE DIRECTIONS

The committee believes that the ACR TI-RADS meets our stated goals, although acknowledging the limitations of our additive approach, which does not fully account for the possibility that the risk conferred by a given ultrasound feature may vary depending on what other features are present in a nodule. As well, several committee members have embarked on a parallel project in which interobserver variability of ultrasound feature assignment will be measured. We plan to revise the ACR TI-RADS periodically as results from this study and other evidence comes to light.

TAKE-HOME POINTS

- The goal of this project is to define a risk stratification system for thyroid nodules (ACR TI-RADS) to guide decisions regarding FNA and follow-up.
- The ACR TI-RADS chart allows practitioners to assign points to nodules based on ultrasound features from a standardized lexicon that lends itself to structured reporting.
- The features that form the basis of this system will be assessed for inter-observer variability in a parallel project.

ACKNOWLEDGMENTS

The authors thank Dr Herbert Chen, chair of the Department of Surgery at the University of Alabama at Birmingham, for reviewing the manuscript. We also are grateful to Dr Xuan V. Nguyen of Ohio State University for performing the SEER data analysis.

ADDITIONAL RESOURCES

Additional resources can be found online at: <http://dx.doi.org/10.1016/j.jacr.2017.01.046>.

REFERENCES

1. Guth S, Theune U, Aberle J, Galach A, Bamberger CM. Very high prevalence of thyroid nodules detected by high frequency (13 MHz) ultrasound examination. *Eur J Clin Invest* 2009;39:699-706.
2. Singh Ospina N, Brito JP, Maraka S, et al. Diagnostic accuracy of ultrasound-guided fine needle aspiration biopsy for thyroid malignancy: systematic review and meta-analysis. *Endocrine* 2016;53:651-61.
3. Smith-Bindman R, Lebda P, Feldstein VA, et al. Risk of thyroid cancer based on thyroid ultrasound imaging characteristics: results of a population-based study. *JAMA Intern Med* 2013;173:1788-96.
4. Ito Y, Uruno T, Nakano K, et al. An observation trial without surgical treatment in patients with papillary microcarcinoma of the thyroid. *Thyroid* 2003;13:381-7.
5. Davies L, Welch HG. Current thyroid cancer trends in the United States. *JAMA Otolaryngol Head Neck Surg* 2014;140:317-22.
6. Ahn HS, Kim HJ, Welch HG. Korea's thyroid-cancer "epidemic"—screening and overdiagnosis. *N Engl J Med* 2014;371:1765-7.
7. Vaccarella S, Franceschi S, Bray F, Wild CP, Plummer M, Dal Maso L. Worldwide thyroid-cancer epidemic? The increasing impact of overdiagnosis. *N Engl J Med* 2016;375:614-7.
8. Grant EG, Tessler FN, Hoang JK, et al. Thyroid ultrasound reporting lexicon: white paper of the ACR Thyroid Imaging, Reporting and Data System (TIRADS) Committee. *J Am Coll Radiol* 2015;12:1272-9.
9. Hoang JK, Langer JE, Middleton WD, et al. Managing incidental thyroid nodules detected on imaging: white paper of the ACR Incidental Thyroid Findings Committee. *J Am Coll Radiol* 2015;12:143-50.
10. Frates MC, Benson CB, Charboneau JW, et al. Management of thyroid nodules detected at US: Society of Radiologists in Ultrasound consensus conference statement. *Radiology* 2005;237:794-800.
11. Horvath E, Majlis S, Rossi R, et al. An ultrasonogram reporting system for thyroid nodules stratifying cancer risk for clinical management. *J Clin Endocrinol Metab* 2009;94:1748-51.
12. Kwak JY, Han KH, Yoon JH, et al. Thyroid imaging reporting and data system for US features of nodules: a step in establishing better stratification of cancer risk. *Radiology* 2011;260:892-9.
13. Na DG, Baek JH, Sung JY, et al. Thyroid imaging reporting and data system risk stratification of thyroid nodules: categorization based on solidity and echogenicity. *Thyroid* 2016;26:562-72.
14. Park JY, Lee HJ, Jang HW, et al. A proposal for a thyroid imaging reporting and data system for ultrasound features of thyroid carcinoma. *Thyroid* 2009;19:1257-64.
15. Seo H, Na DG, Kim JH, Kim KW, Yoon JW. Ultrasound-based risk stratification for malignancy in thyroid nodules: a four-tier categorization system. *Eur Radiol* 2015;25:2153-62.

16. Russ G. Risk stratification of thyroid nodules on ultrasonography with the French TI-RADS: description and reflections. *Ultrasonography* 2016;35:25-38.
17. Shin JH, Baek JH, Chung J, et al. Ultrasonography Diagnosis and Imaging-Based Management of Thyroid Nodules: Revised Korean Society of Thyroid Radiology Consensus Statement and Recommendations. *Korean J Radiol* 2016;17:370-95.
18. Zayadeen AR, Abu-Yousef M, Berbaum K. Retrospective evaluation of ultrasound features of thyroid nodules to assess malignancy risk: a step toward TIRADS. *AJR Am J Roentgenol* 2016;207:460-9.
19. Haugen BR, Alexander EK, Bible KC, et al. 2015 American Thyroid Association management guidelines for adult patients with thyroid nodules and differentiated thyroid cancer: the American Thyroid Association Guidelines Task Force on Thyroid Nodules and Differentiated Thyroid Cancer. *Thyroid* 2016;26:1-133.
20. Magri F, Chytiris S, Chiovato L. The role of elastography in thyroid ultrasonography. *Curr Opin Endocrinol Diabetes Obes* 2016;23:416-22.
21. Park VY, Kim EK, Kwak JY, Yoon JH, Kim MJ, Moon HJ. Thyroid imaging reporting and data system and ultrasound elastography: diagnostic accuracy as a tool in recommending repeat fine-needle aspiration for solid thyroid nodules with non-diagnostic fine-needle aspiration cytology. *Ultrason Med Biol* 2016;42:399-406.
22. Hoang JK, Nguyen XV, Davies L. Overdiagnosis of thyroid cancer: answers to five key questions. *Acad Radiol* 2015;22:1024-9.
23. Ito Y, Miyauchi A. Nonoperative management of low-risk differentiated thyroid carcinoma. *Curr Opin Oncol* 2015;27:15-20.
24. Leboulleux S, Tuttle RM, Pacini F, Schlumberger M. Papillary thyroid microcarcinoma: time to shift from surgery to active surveillance? *Lancet Diabetes Endocrinol* 2016;4:933-42.
25. Yoon JH, Lee HS, Kim EK, Moon HJ, Kwak JY. Malignancy risk stratification of thyroid nodules: comparison between the Thyroid Imaging Reporting and Data System and the 2014 American Thyroid Association management guidelines. *Radiology* 2016;278:917-24.
26. Machens A, Holzhausen HJ, Dralle H. The prognostic value of primary tumor size in papillary and follicular thyroid carcinoma. *Cancer* 2005;103:2269-73.
27. Deveci MS, Deveci G, LiVolsi VA, Gupta PK, Baloch ZW. Concordance between thyroid nodule sizes measured by ultrasound and gross pathology examination: effect on patient management. *Diagn Cytopathol* 2007;35:579-83.
28. Bachar G, Buda I, Cohen M, et al. Size discrepancy between sonographic and pathological evaluation of solitary papillary thyroid carcinoma. *Eur J Radiol* 2013;82:1899-903.
29. Middleton WD, Teeffey SA, Reading C, et al. Multi-institutional analysis of thyroid nodule risk stratification using the American College of Radiology Thyroid Imaging, Reporting and Data System. *AJR Am J Roentgenol*. In press.
30. Nguyen XV, Choudhury KR, Eastwood JD, et al. Incidental thyroid nodules on CT: evaluation of 2 risk-categorization methods for work-up of nodules. *AJNR Am J Neuroradiol* 2013;34:1812-7.
31. Lacout A, Chevenet C, Marcy PY. Mummified thyroid syndrome. *AJR Am J Roentgenol* 2016;206:837-45.
32. Bonavita JA, Mayo J, Babb J, et al. Pattern recognition of benign nodules at ultrasound of the thyroid: which nodules can be left alone? *AJR Am J Roentgenol* 2009;193:207-13.
33. Reading CC, Charboneau JW, Hay ID, Sebo TJ. Sonography of thyroid nodules: a "classic pattern" diagnostic approach. *Ultrasound Q* 2005;21:157-65.
34. Virmani V, Hammond I. Sonographic patterns of benign thyroid nodules: verification at our institution. *AJR Am J Roentgenol* 2011;196:891-5.
35. Kim DW, Lee EJ, In HS, Kim SJ. Sonographic differentiation of partially cystic thyroid nodules: a prospective study. *AJNR Am J Neuroradiol* 2010;31:1961-6.
36. Kim DW, Park JS, In HS, Choo HJ, Ryu JH, Jung SJ. Ultrasound-based diagnostic classification for solid and partially cystic thyroid nodules. *AJNR Am J Neuroradiol* 2012;33:1144-9.
37. Lee MJ, Kim EK, Kwak JY, Kim MJ. Partially cystic thyroid nodules on ultrasound: probability of malignancy and sonographic differentiation. *Thyroid* 2009;19:341-6.
38. Park JM, Choi Y, Kwag HJ. Partially cystic thyroid nodules: ultrasound findings of malignancy. *Korean J Radiol* 2012;13:530-5.
39. Rosario PW, Silva AL, Borges MA, Calsolari MR. Is Doppler ultrasound of additional value to gray-scale ultrasound in differentiating malignant and benign thyroid nodules? *Arch Endocrinol Metab* 2015;59:79-83.
40. Moon WJ, Jung SL, Lee JH, Na DG, Baek JH, Lee YH, et al. Benign and malignant thyroid nodules: US differentiation—multicenter retrospective study. *Radiology* 2008;247:762-70.
41. Youngwirth LM, Adam MA, Scheri RP, Roman SA, Sosa JA. Extrathyroidal extension is associated with compromised survival in patients with thyroid cancer. *Thyroid*. In press.
42. Mete O, Rotstein L, Asa SL. Controversies in thyroid pathology: thyroid capsule invasion and extrathyroidal extension. *Ann Surg Oncol* 2010;17:386-91.
43. Hoang JK, Lee WK, Lee M, Johnson D, Farrell S. US Features of thyroid malignancy: pearls and pitfalls. *Radiographics* 2007;27:847-60.
44. Kamaya A, Tahvildari AM, Patel BN, Willmann JK, Jeffrey RB, Desser TS. Sonographic detection of extracapsular extension in papillary thyroid cancer. *J Ultrasound Med* 2015;34:2225-30.
45. Kim H, Kim JA, Son EJ, et al. Preoperative prediction of the extrathyroidal extension of papillary thyroid carcinoma with ultrasonography versus MRI: a retrospective cohort study. *Int J Surg* 2014;12:544-8.
46. Su HK, Wenig BM, Haser GC, et al. Inter-observer variation in the pathologic identification of minimal extrathyroidal extension in papillary thyroid carcinoma. *Thyroid* 2016;26:512-7.
47. Hay ID, Johnson TR, Thompson GB, Sebo TJ, Reinalda MS. Minimal extrathyroid extension in papillary thyroid carcinoma does not result in increased rates of either cause-specific mortality or postoperative tumor recurrence. *Surgery* 2016;159:11-9.
48. Shin JH, Ha TK, Park HK, et al. Implication of minimal extrathyroidal extension as a prognostic factor in papillary thyroid carcinoma. *Int J Surg* 2013;11:944-7.
49. Kim MJ, Kim EK, Kwak JY, et al. Differentiation of thyroid nodules with macrocalcifications: role of suspicious sonographic findings. *J Ultrasound Med* 2008;27:1179-84.
50. Na DG, Kim DS, Kim SJ, Ryoo JW, Jung SL. Thyroid nodules with isolated macrocalcification: malignancy risk and diagnostic efficacy of fine-needle aspiration and core needle biopsy. *Ultrasonography* 2016;35:212-9.
51. Taki S, Terahata S, Yamashita R, et al. Thyroid calcifications: sonographic patterns and incidence of cancer. *Clin Imaging* 2004;28:368-71.
52. Arpaci D, Ozdemir D, Cuhaci N, et al. Evaluation of cytopathological findings in thyroid nodules with macrocalcification: macrocalcification is not innocent as it seems. *Arq Bras Endocrinol Metabol* 2014;58:939-45.
53. Park YJ, Kim JA, Son EJ, et al. Thyroid nodules with macrocalcification: sonographic findings predictive of malignancy. *Yonsei Med J* 2014;55:339-44.
54. Malhi H, Beland MD, Cen SY, et al. Echogenic foci in thyroid nodules: significance of posterior acoustic artifacts. *AJR Am J Roentgenol* 2014;203:1310-6.
55. Brito JP, Hay ID, Morris JC. Low risk papillary thyroid cancer. *BMJ* 2014;348:g3045.
56. Brito JP, Ito Y, Miyauchi A, Tuttle RM. A clinical framework to facilitate risk stratification when considering an active surveillance

- alternative to immediate biopsy and surgery in papillary microcarcinoma. *Thyroid* 2016;26:144-9.
57. Ito Y, Miyauchi A, Inoue H, et al. An observational trial for papillary thyroid microcarcinoma in Japanese patients. *World J Surg* 2010;34:28-35.
 58. Choi YJ, Baek JH, Hong MJ, Lee JH. Inter-observer variation in ultrasound measurement of the volume and diameter of thyroid nodules. *Korean J Radiol* 2015;16:560-5.
 59. Burch HB, Burman KD, Cooper DS, Hennessey JV, Viator NO. A 2015 survey of clinical practice patterns in the management of thyroid nodules. *J Clin Endocrinol Metab* 2016;101:2853-62.
 60. Magister MJ, Chaikhoutdinov I, Schaefer E, Williams N, Saunders B, Goldenberg D. Association of thyroid nodule size and Bethesda class with rate of malignant disease. *JAMA Otolaryngol Head Neck Surg* 2015;141:1089-95.
 61. Nakamura H, Hirokawa M, Ota H, Kihara M, Miya A, Miyauchi A. Is an increase in thyroid nodule volume a risk factor for malignancy? *Thyroid* 2015;25:804-11.
 62. Ajmal S, Rapoport S, Ramirez Batlle H, Mazzaglia PJ. The natural history of the benign thyroid nodule: what is the appropriate follow-up strategy? *J Am Coll Surg* 2015;220:987-92.
 63. Durante C, Costante G, Lucisano G, et al. The natural history of benign thyroid nodules. *JAMA* 2015;313:926-35.
 64. AIUM practice parameter for the performance of a thyroid and parathyroid ultrasound examination. *J Ultrasound Med* 2016;35:1-11.
 65. Ahuja AT, Ying M, Ho SY, et al. Ultrasound of malignant cervical lymph nodes. *Cancer Imaging* 2008;8:48-56.
 66. Leboulleux S, Girard E, Rose M, et al. Ultrasound criteria of malignancy for cervical lymph nodes in patients followed up for differentiated thyroid cancer. *J Clin Endocrinol Metab* 2007;92:3590-4.
 67. Patel NU, McKinney K, Kreidler SM, et al. Ultrasound-based clinical prediction rule model for detecting papillary thyroid cancer in cervical lymph nodes: a pilot study. *J Clin Ultrasound* 2016;44:143-51.