

Edward G. Grant, MD
 Carol B. Benson, MD
 Gregory L. Moneta, MD
 Andrei V. Alexandrov, MD, RVT
 J. Dennis Baker, MD
 Edward I. Bluth, MD
 Barbara A. Carroll, MD
 Michael Eliasziw, PhD
 John Gocke, MD, MPH, RVT
 Barbara S. Hertzberg, MD
 Sandra Katanick, RN, RVT
 Laurence Needleman, MD
 John Pellerito, MD
 Joseph F. Polak, MD
 Kenneth S. Rholl, MD
 Douglas L. Wooster, MD, RVT
 Eugene Zierler, MD

Index terms:

Carotid arteries, flow dynamics
 Carotid arteries, stenosis or
 obstruction, 172.4311, 172.4312,
 172.721

Carotid arteries, US, 172.12981,
 172.12983, 172.12984

Special Reports

Published online before print

10.1148/radiol.2292030516
Radiology 2003; 229:340–346

¹ From the Dept of Radiology, Univ of Southern California, Keck School of Medicine, USC University Hospital, 1500 San Pablo St, Los Angeles, CA 90033 (E.G.G.); Dept of Radiology, Brigham and Women's Hosp, Harvard Med School, Boston, Mass (C.B.B., J.F.F.); Dept of Surgery, Oregon Health and Science Univ, Portland, Ore (G.L.M.); Cerebrovascular Ultrasound and Stroke Treatment Team, Univ of Texas Houston Med School (A.V.A.); Dept of Surgery, West Los Angeles VA Med Ctr, Calif (J.D.B.); Dept of Radiology, Ochsner Clinic, New Orleans, La (E.I.B.); Dept of Radiology, Duke Univ Med School, Durham, NC (B.A.C., B.S.H.); Dept of Biostatistics, Univ of Calgary, Alberta, Canada (M.E.); Midwest Heart Specialists Vascular Lab and La Grange Memorial Vascular Laboratory, Downers Grove, Ill (J.G.); Intersocietal Accreditation Commission, Columbia, Md (S.K.); Dept of Radiology, Thomas Jefferson Univ, Philadelphia, Pa (L.N.); Dept of Radiology, North Shore Univ Hosp, New York Univ School of Med, NY (J.P.); Dept of Radiology, Inova Alexandria Hosp, Va (K.S.R.); Dept of Surgery, Univ of Toronto, Ontario, Canada (D.L.W.); and Dept of Surgery, Univ of Washington Med School, Seattle (R.E.Z.). Received Apr 1, 2003; revision requested May 7; revision received May 21; accepted May 22. **Address correspondence** to E.G.G. (e-mail: edgrant@usc.edu).

© RSNA, 2003

Carotid Artery Stenosis: Gray-Scale and Doppler US Diagnosis—Society of Radiologists in Ultrasound Consensus Conference¹

The Society of Radiologists in Ultrasound convened a multidisciplinary panel of experts in the field of vascular ultrasonography (US) to come to a consensus regarding Doppler US for assistance in the diagnosis of carotid artery stenosis. The panel's consensus statement is believed to represent a reasonable position on the basis of analysis of available literature and panelists' experience. Key elements of the statement include the following: (a) All internal carotid artery (ICA) examinations should be performed with gray-scale, color Doppler, and spectral Doppler US. (b) The degree of stenosis determined at gray-scale and Doppler US should be stratified into the categories of normal (no stenosis), <50% stenosis, 50%–69% stenosis, ≥70% stenosis to near occlusion, near occlusion, and total occlusion. (c) ICA peak systolic velocity (PSV) and presence of plaque on gray-scale and/or color Doppler images are primarily used in diagnosis and grading of ICA stenosis; two additional parameters, ICA-to-common carotid artery PSV ratio and ICA end-diastolic velocity may also be used when clinical or technical factors raise concern that ICA PSV may not be representative of the extent of disease. (d) ICA should be diagnosed as (i) normal when ICA PSV is less than 125 cm/sec and no plaque or intimal thickening is visible; (ii) <50% stenosis when ICA PSV is less than 125 cm/sec and plaque or intimal thickening is visible; (iii) 50%–69% stenosis when ICA PSV is 125–230 cm/sec and plaque is visible; (iv) ≥70% stenosis to near occlusion when ICA PSV is greater than 230 cm/sec and visible plaque and lumen narrowing are seen; (v) near occlusion when there is a markedly narrowed lumen at color Doppler US; and (vi) total occlusion when there is no detectable patent lumen at gray-scale US and no flow at spectral, power, and color Doppler US. (e) The final report should discuss velocity measurements and gray-scale and color Doppler findings. Study limitations should be noted when they exist. The conclusion should state an estimated degree of ICA stenosis as reflected in the above categories. The panel also considered various technical aspects of carotid US and methods for quality assessment and identified several important unanswered questions meriting future research.

© RSNA, 2003

A panel of experts from a variety of medical specialties was convened under the auspices of the Society of Radiologists in Ultrasound to arrive at a consensus about the performance of Doppler ultrasonography (US) to aid in diagnosis of internal carotid artery (ICA) stenosis. The panel met in San Francisco, Calif, October 22–23, 2002, and drew up a consensus statement. Although there are several facets of carotid disease that could be considered by such a panel, carotid stenosis (and by extension, carotid occlusion) is by far the most common pathologic process involving carotid arteries. Furthermore, the clinical suspicion of ICA stenosis is responsible for most of the referrals for carotid imaging. Authors of recent major studies have shown a decrease in stroke risk when carotid endarterectomy is performed for carotid stenosis (1–4).

The performance of carotid US and the interpretation of US results vary considerably

TABLE 1
Literature Review of Doppler US Thresholds and Performance in Diagnosis of ICA Stenosis

Study and Year	Threshold				Performance				
	Stenosis (%)	PSV (cm/sec)	EDV (cm/sec)	Ratio	Sensitivity (%)	Specificity (%)	PPV (%)	NPV (%)	Accuracy (%)
Huston et al (6), 2000	50	130	...	1.6	92	90	90	91	91
	70	230	70	3.2	86	90	83	92	89
Grant et al (7), 1999	60	200	...	3	AP*	AP*	AP*	AP*	AP*
	70	175	...	2.5	SP*	SP*	SP*	SP*	SP*
Abu Rahma et al (8), 1998	50	140	92	95	97	89	93
	60	150	65	...	82	97	96	86	90
	70	150	90	...	85	95	91	92	92
Carpenter et al (9), 1996	70	210	94	77	68	96	83
	70	...	70	...	92	60	73	86	77
	70	3.3	100	65	65	100	79
Hood et al (10), 1996	70	130	100	...	78	97	88	94	93
Carpenter et al (11), 1995	60	170	98	87	88	98	92
	60	...	40	...	97	52	86	86	86
	60	2.0	97	73	78	96	76
	60	230	40	2.0	100	100	100	100	100
Browerman et al (12), 1995	70	175	91	60
Moneta et al (13), 1995	60	260	70	3.2-3.5	84	94	92	88	90
Neale et al (14), 1994	70	270	110	...	96	91	93
Moneta et al (15), 1993	70	325	130	...	83	90	80	92	88

Note.—EDV = end diastolic velocity in ICA, NPV = negative predictive value, PPV = positive predictive value, PSV = peak systolic velocity in ICA. Ratio is ICA PSV to distal common carotid artery (CCA) PSV.

* AP = asymptomatic patients, SP = symptomatic patients. Thresholds based on outcome > sensitivity/specificity > accuracy.

from laboratory to laboratory (5). Accreditation of vascular laboratories has resulted in an increased degree of standardization of the carotid US examination, but a wide range of practice patterns still exist. The goal of the conference was to develop recommendations for the performance of Doppler US and interpretation of the results in the diagnosis of ICA stenosis. The panel limited its discussion to atherosclerotic stenosis of the ICA at or just beyond the carotid bifurcation and to vessels without prior intervention.

METHODS AND CONFERENCE PREPARATIONS

Conference Participants

Prior to the meeting, 30 representative articles were selected by the moderator (E.G.G.) and sent to conference participants, along with a summary spreadsheet with such information as the purpose of the research, the statistical methods used, and the pertinent results and conclusions (Tables 1, 2) (6-26). The panel consisted of a moderator and 16 panelists from various medical specialties.

Background and Summary of the Literature

Historically, clinical studies of carotid artery disease have classified patients in two groups: symptomatic and asymptomatic. The former group of patients

typically has had a neurologic event (stroke, transient ischemic attack, or amaurosis fugax) secondary to cerebral ischemia, likely as a result of an embolic event arising from atherosclerotic disease at the carotid bifurcation. Patients in this group have formed the basis for such well-known studies as the North American Symptomatic Carotid Endarterectomy Trial (1) and the European Symptomatic Carotid Trial (3).

The asymptomatic group includes patients who have not had a neurologic event. The seminal investigation in this population, the Asymptomatic Carotid Artery Study (2), included patients who, though they had not had a neurologic event, typically had clinical markers for diffuse atherosclerosis. Overall, the prevalence of significant (>50%) stenotic disease in symptomatic patients is stated as being in the range of 18%-20% (27,28), while the prevalence in asymptomatic patients referred for carotid imaging is 14% (29). The prevalence of ICA disease in the asymptomatic group, therefore, approaches that found in symptomatic patients.

Doppler US is by far the most common imaging examination performed worldwide to aid in the diagnosis of carotid disease. Given the prevalence of patients with carotid disease and the frequency with which patients are referred for carotid imaging, the number of carotid US

examinations performed annually is considerable (22). This imaging modality is increasingly becoming the only examination performed before surgical intervention. It was estimated by the panelists that as many as 80% of patients in the United States undergo carotid endarterectomy after a US examination as the only preoperative imaging study. Therefore, it is of utmost importance that information provided by the US examination be reproducible and reliable.

Considerable gains have been made in the quality of US examinations of the carotid arteries over the past 2 decades. The technology has experienced great advances in equipment, ranging from continued improvements in gray-scale resolution to landmark advances in Doppler methods, including color Doppler imaging. The imaging community has gained expertise in performance of carotid US and interpretation of the results through widespread use of technology, research, and continuing medical education. In addition, various accrediting bodies have been established by groups such as the Intersocietal Commission for Accreditation of Vascular Laboratories, the American Institute of Ultrasound in Medicine, and the American College of Radiology in an attempt to improve and standardize the quality of vascular US examinations.

Despite improvements and advances,

TABLE 2
Other Pertinent Literature on ICA Stenosis

Study and Year	Threshold Chosen*			Assessment and Results
	Stenosis (%)	PSV (cm/sec)	Ratio [†]	
Umemura and Yamada (16), 2001	NA	NA	NA	Evaluated results of B-flow imaging without Doppler
Perkins et al (17), 2000	NA	NA	NA	Survey results show that laboratories use inconsistent thresholds
Grant et al (18), 2000	NA	NA	NA	Doppler US cannot be used to estimate a single degree of stenosis but is better for differentiating less than or more than a single degree of stenosis
Beebe et al (19), 1999	NA	NA	NA	Color and gray scale perform well alone; Doppler helps for midrange lesions
Soulez et al (20), 1999	70, 60	NA	3.4, 2.9	Ratio of ICA PSV at and distal to stenosis performs better than ICA/CCA ratio
Ranke et al (21), 1999	70	NA	NA	Ratio of ICA PSV at stenosis to that distal to stenosis: sensitivity, 97%, specificity, 98%
Derdeyn and Powers (22), 1996	60	230	NA	Evaluation of cost-effectiveness of asymptomatic screening
Griewig et al (23), 1996	NA	NA	NA	Power Doppler better than color Doppler (not quantified)
Srinivasan et al (24), 1995	NA	NA	NA	Doppler poor for differentiating degree of <50% stenosis
Hunink et al (25), 1993	70	230	NA	PSV best parameter for predicting >70% stenosis
Bluth et al (26), 1988	NA	NA	NA	EDV best Doppler parameter; did not use NASCET angiography criteria [‡]

* NA = not applicable.

[†] Ratio is ICA PSV to distal CCA PSV.

[‡] NASCET = North American Symptomatic Carotid Endarterectomy Trial.

the consensus panel agreed that, overall, carotid US is often performed inconsistently within a given laboratory, and there is nonuniformity in practice from one laboratory to the next. In many settings, interpretive criteria for carotid stenosis are either indiscriminately applied or the interpreters are uncertain about exactly how to make the diagnosis of carotid stenosis.

CONSENSUS CONFERENCE

The results of the consensus conference regarding performance of carotid US and interpretation of the results and the diagnosis of ICA stenosis can be summarized into six key areas: (a) technical considerations, (b) diagnostic strata, (c) imaging and Doppler parameters, (d) Doppler diagnostic thresholds; (e) the final report of the gray-scale and Doppler US examinations, and (f) quality assessment. The panel identified a number of issues related to performance of carotid US and interpretation of the results and made recommendations to address these issues.

Technical Considerations Standardization

Issue.—The performance of carotid US examinations is not standardized from laboratory to laboratory. Even within a

given laboratory, there is often a failure to follow a consistent protocol.

Recommendation.—Examinations of the ICA should be performed with gray-scale, color Doppler, and spectral Doppler US in a standardized fashion, according to a rigidly applied laboratory protocol, in accordance with the standards of one of the accrediting bodies. The panel encourages all sonographers performing carotid US to become credentialed as vascular technologists.

Positioning and Angulation

Issue.—Errors in positioning the Doppler gate and in accounting for the Doppler angle are common in current clinical practices. Since interpretive criteria for carotid stenosis are heavily based on Doppler velocities, errors in Doppler position and angle correction will lead to serious errors in diagnosis.

Recommendation.—The Doppler waveform should be obtained with an angle of insonation less than or equal to 60°, as measurements obtained with an angle of insonation greater than 60° are likely to be inaccurate, even with appropriate angle adjustment, because of the physical properties of Doppler.

Conflicting opinions.—Some believed that maintaining a constant angle of insonation of exactly 60° would provide

greater consistency. Other panelists did not agree that a fixed angle of insonation for all carotid US examinations is required and instead expressed that it is necessary only to maintain an angle of less than or equal to 60°. It was thought that further investigation on this matter is warranted.

Sample Volume Position

Issue.—Other common technical shortcomings in ICA examinations include incorrect positioning of the sample volume, incomplete sampling through an area of stenosis, and failure to depict the distal end of a carotid plaque.

Recommendation.—Care should be taken to position the sample volume within the area of greatest stenosis. The ICA must be sampled through the region of stenosis completely until the distal end of the plaque is visualized, to ensure that the site of highest velocity has been located.

Patient Considerations

Issue.—Several errors may result from problems inherent to the patient, such as extensive plaque calcification, severe ICA tortuosity, and tandem lesions.

Recommendation.—It is important to recognize these patient conditions and understand that, in such cases, the examination may be limited.

Equipment

Issue.—There is substantial variability in equipment from machine to machine, from manufacturer to manufacturer, and between older and newer equipment (30–33). This variability in equipment may explain, in part, the lack of agreement and inconsistency in the literature concerning Doppler thresholds for the diagnosis of carotid stenosis.

Recommendation.—The panel encourages US equipment manufacturers to minimize equipment variability by establishing industry-wide standards for Doppler measurement and calibration and the development of a reliable Doppler phantom that can be made readily available to industry and to vascular laboratories.

Diagnostic Strata

Methods of Reporting

Issue.—Methods by which the degree of ICA stenosis is reported vary from laboratory to laboratory, as well as within some laboratories. Some report an estimate of the specific percentage of stenosis, others stratify their estimates into five or six diagnostic categories or gradations of stenosis.

Recommendation.—Doppler US cannot be used to predict a single percentage of stenosis. Therefore, the consensus panelists strongly recommend the use of defined diagnostic strata. Laboratories should establish protocols for stratifying the degree of ICA stenosis, and, once established, these criteria should be consistently applied.

Doppler Measurement Variability

Although investigators have confirmed that the average Doppler velocity rises in direct proportion to the degree of stenosis as determined with angiography (18,26), there are very wide ranges of Doppler values around those means, which makes it impossible to classify lesions into gradations as narrow as 10% (Figure) (18,34). Even in evaluations of the ability of Doppler US to help estimate the degree of stenosis by using more expanded strata (eg, <50%, 50%–69%, and ≥70% stenosis), the findings have been disappointing. US is most accurate when lesions are classified as being above or below a single level, such as 60% stenosis or 70% stenosis (18).

Stenosis of Less than 50%

Issue.—In many laboratories, stratification or diagnosis of minor (<50%) de-

grees of ICA stenosis is based on Doppler findings.

Recommendation.—Because Doppler is inaccurate for subcategorizing stenoses less than 50%, these stenoses should be reported under a single category as “<50% stenosis.” Subcategories for minor degrees of stenosis should not be used.

Stratification of Stenoses

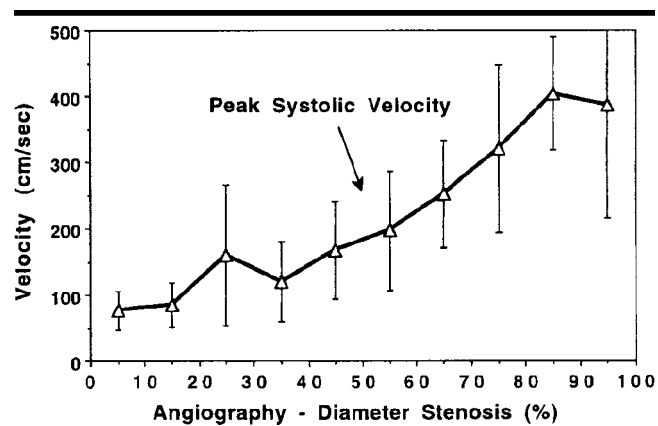
Issue.—How should reporting of ICA stenosis be stratified?

Recommendation.—The consensus panel recommends stratification of the degree of stenosis on the basis of gray-scale and Doppler US results into the following strata: normal (no stenosis), <50% stenosis, 50%–69% stenosis, ≥70% stenosis but less than near occlusion, near occlusion, and total occlusion.

Discussion.—The threshold of 70% stenosis was chosen because it was believed to be the threshold currently used by most major vascular centers for surgical intervention. The panel agreed, however, that in some laboratories, there may be a compelling reason to choose a different stratification scheme. The diagnoses of near occlusion and total occlusion are usually not based primarily on the Doppler measurement of velocity but rather on gray-scale and color and/or power Doppler imaging.

Imaging and Doppler Parameters Key Components of ICA Examination

Issue.—What are the key components of the US examination of the ICA?



Graph demonstrates the relationship between mean PSV and percentage of stenosis as measured arteriographically. PSV increases with increasing severity of stenosis. Note marked overlap in adjacent categories of stenosis. Error bars = 1 SD about the mean. (Reprinted, with permission, from reference 18.)

Recommendation.—The ICA US examination should consist of gray-scale imaging, color Doppler imaging, and spectral Doppler velocity determination. Because stenosis is typically an area of narrowing caused by plaque, with a focal area of increased velocity and a poststenotic disturbed flow, the location and characteristics of plaque in the ICA should be determined. The color Doppler appearance of the lumen should also be assessed.

Primary US Parameters

Issue.—Numerous imaging and Doppler parameters are currently used at various laboratories for the evaluation of ICA stenosis, including ICA PSV, ICA EDV and ICA/CCA PSV ratio, CCA EDV, and ICA/CCA EDV ratio. The application of these parameters for diagnosis of ICA stenosis varies from laboratory to laboratory and sometimes within a given laboratory.

Recommendation.—The panel suggested that the ICA PSV and the presence of plaque on gray-scale and/or color Doppler US images are the parameters that should be used when diagnosing and grading ICA stenosis.

Discussion.—The ICA PSV is easy to obtain and has good reproducibility and should be used in conjunction with available gray-scale and color Doppler information to ensure concordance of diagnostic information. The degree of stenosis estimated by using ICA PSV and the degree of narrowing of the ICA lumen on gray-scale and color Doppler images should be similar.

TABLE 3
Consensus Panel Gray-Scale and Doppler US Criteria for Diagnosis of ICA Stenosis

Degree of Stenosis (%)	Primary Parameters		Additional Parameters	
	ICA PSV (cm/sec)	Plaque Estimate (%)*	ICA/CCA PSV Ratio	ICA EDV (cm/sec)
Normal	<125	None	<2.0	<40
<50	<125	<50	<2.0	<40
50–69	125–230	≥50	2.0–4.0	40–100
≥70 but less than near occlusion	>230	≥50	>4.0	>100
Near occlusion	High, low, or undetectable	Visible	Variable	Variable
Total occlusion	Undetectable	Visible, no detectable lumen	Not applicable	Not applicable

* Plaque estimate (diameter reduction) with gray-scale and color Doppler US.

Additional US Parameters

Issue.—Should other Doppler parameters be used and, if so, when?

Recommendation.—Two additional parameters, ICA/CCA PSV ratio and ICA EDV, are useful for internal checks or may be used when ICA PSV may not be representative of the extent of disease owing to technical or clinical factors such as in the presence of tandem lesions, contralateral high-grade stenosis, discrepancy between visual assessment of plaque and ICA PSV, elevated CCA velocity, hyperdynamic cardiac state, or low cardiac output. For example, in a patient with low cardiac output, the ICA PSV may be disproportionately low when compared with the ICA/CCA PSV ratio. This discrepancy should prompt the interpreter to consider all gray-scale and Doppler information when stratifying the degree of ICA stenosis. In particular in such cases, the interpretation should be based more heavily on the ICA/CCA PSV ratio than on absolute values such as the ICA PSV or ICA EDV. The panel believed that outlining the reasons for making diagnostic choices that are not in keeping with usual practice should be included in the final report.

Doppler Diagnostic Thresholds

Issue.—Published literature is replete with velocity thresholds for categorizing ICA stenosis (Table 1). Tremendous variation exists among these studies in the methods used to assess individual Doppler parameters and in the thresholds recommended for diagnosing ICA stenosis (7).

Recommendation.—The consensus panel developed recommendations for diagnosis

and stratification of ICA stenosis (Table 3). These recommendations were derived from analysis of numerous studies and do not represent the results of any one laboratory or study. For a particular laboratory setting, internal validation is encouraged when possible. This may yield alternative diagnostic criteria that can be used successfully at that facility. However, each laboratory should have a single set of diagnostic criteria that is applied uniformly. The following points are included in Table 3 and should be considered in the diagnosis of ICA stenosis:

1. The ICA is considered **normal** when ICA PSV is less than 125 cm/sec and no plaque or intimal thickening is visible sonographically. Additional criteria include ICA/CCA PSV ratio < 2.0 and ICA EDV < 40 cm/sec.

2. A **<50% ICA stenosis** is diagnosed when ICA PSV is less than 125 cm/sec and plaque or intimal thickening is visible sonographically. Additional criteria include ICA/CCA PSV ratio < 2.0 and ICA EDV < 40 cm/sec.

3. A **50%–69% ICA stenosis** is diagnosed when ICA PSV is 125–230 cm/sec and plaque is visible sonographically. Additional criteria include ICA/CCA PSV ratio of 2.0–4.0 and ICA EDV of 40–100 cm/sec.

4. A **≥70% ICA stenosis** but less than near occlusion of the ICA is diagnosed when the ICA PSV is greater than 230 cm/sec and visible plaque and luminal narrowing are seen at gray-scale and color Doppler US. Additional criteria include ICA/CCA PSV ratio > 4 and ICA EDV > 100 cm/sec. The higher the Doppler parameter lies above the threshold of 230 cm/sec, the greater the likelihood of severe disease.

5. In cases of **near occlusion** of the ICA, the velocity parameters may not apply, since velocities may be high, low, or undetectable. This diagnosis is established primarily by demonstrating a markedly narrowed lumen at color or power Doppler US (35).

6. **Total occlusion** of the ICA should be suspected when there is no detectable patent lumen at gray-scale US and no flow with spectral, power, and color Doppler US. Magnetic resonance (MR) angiography, computed tomographic (CT) angiography, or conventional angiography may be used for confirmation in this setting (35).

Final Report of the Gray-Scale and Doppler US Examination

Issue.—The structure and content of final reports of carotid US examinations vary greatly from laboratory to laboratory, as well as within given laboratories.

Recommendation.—The final report of the gray-scale and Doppler US interpretation of the ICA examination should include the following:

Body of the report.—(a) Pertinent US findings, including velocity measurements and gray-scale findings (presence, location, and characteristics of ICA plaque), as well as color Doppler findings when appropriate; (b) comments about limitations of the study or deviations from usual interpretive criteria due to technical factors or hemodynamic considerations; and (c) comparison with results of prior studies.

Conclusion or impression.—Estimated degree of ICA stenosis, categorized by the laboratory's established diagnostic criteria (modified, as appropriate, by technical factors or hemodynamic considerations).

Quality Assessment

Need for Quality Assessment

Issue.—Should every laboratory have a system for quality assessment?

Recommendation.—All laboratories should institute a program of quality assessment.

Internal Validation of Doppler Thresholds

Issue.—Development of internally validated Doppler thresholds may be difficult given the infrequency of correlative angiograms at most institutions.

Recommendation.—The panel agreed that it may not always be feasible to obtain angiographic or clinical correlation for quality assessment of US studies at

each laboratory. For this reason, the consensus panel developed the table of recommended Doppler thresholds for diagnosis of ICA stenosis (Table 3), which can be applied at laboratories that cannot validate their own Doppler thresholds on the basis of correlative imaging or clinical information.

Discussion.—Although angiography has historically been considered the “gold standard” for assessing Doppler thresholds for various degrees of ICA stenosis, few angiographic examinations are still performed. Those that are performed at a given institution are probably not representative cases, but rather those cases in which the US results were equivocal or otherwise problematic. The use of CT angiography and MR angiography for correlation has not, as yet, been fully validated (36).

Reference Standard

Issue.—When angiography is used as the reference standard for assessment of Doppler criteria for ICA stenosis, different techniques for measuring ICA stenosis have been used.

Recommendation.—The panel recommended that the NASCET method of carotid stenosis measurement should be employed when angiography is used to correlate the US findings.

Discussion.—In this method, the narrowest portion of the vascular lumen was compared with the “normalized lumen distally” (37). In the European Symptomatic Carotid Trial study and studies performed prior to the NASCET study, the degree of stenosis was determined by comparing the narrowest diameter of the residual lumen to an estimate of the original lumen in the same area. Because the original lumen cannot be depicted on the angiogram, exact measurement is impossible. While the NASCET method of measurement may not reflect the burden of atherosclerosis in the proximal ICA, it does minimize the amount of interobserver variability.

OTHER CONSIDERATIONS

Patient Surveillance

The panel discussed the issue of appropriate follow-up of asymptomatic patients with known ICA stenosis, as well as of patients at high risk for ICA stenosis or stroke. The panelists agreed that patients with a $\geq 50\%$ stenosis of the ICA who do not undergo carotid endarterectomy and who may be candidates for prophylactic carotid endarterectomy should be fol-

lowed up at 6–12-month intervals, and high-risk patients with visible plaque and $<50\%$ stenosis should be evaluated every 1–2 years. Patients who have normal carotid US studies but marked risk factors might be evaluated every 3–5 years. In all cases of follow-up or surveillance, a complete examination should be performed. Follow-up studies should be compared with results from prior examinations.

Research Topics

The panel identified several important unanswered questions that merit future research.

1. What is the role of ICA plaque characterization in carotid disease?

2. What is the role of the ICA intimal-medial thickness? There are several ongoing large clinical trials in which the intimal-medial thickness is being evaluated as a marker of atherosclerotic disease, but there are not yet enough data to establish the role of this measurement in the assessment of carotid disease in individual patients.

3. At follow-up examination, how much of a change in estimated ICA stenosis or ICA PSV should be considered relevant?

4. What criteria should be used to assess patients after ICA surgery or stent placement?

5. Should US be used to screen for carotid disease?

Other issues that need to be addressed include the following:

1. There is considerable variation in Doppler measurements from machine to machine and manufacturer to manufacturer. This should be rectified, because such variation leads to inconsistencies and inaccuracies in diagnosing ICA stenosis.

2. Phantoms for Doppler US need to be developed to facilitate calibration of Doppler US equipment.

3. Improved methods for calculating velocity with angle correction should be developed to eliminate or minimize the inconsistency in velocity measurements as the Doppler angle of insonation is changed.

4. Reliable quality assessment methods should be developed so that laboratories can assess their performance of the carotid US examination. This should lead to greater consistency in the performance of carotid US within each laboratory, as well as from laboratory to laboratory.

References

1. North American Symptomatic Carotid Endarterectomy Trial collaborators. Bene-

ficial effect of carotid endarterectomy in symptomatic patients with high-grade carotid stenosis. *N Engl J Med* 1991; 325:445–453.

2. Executive Committee for the Asymptomatic Carotid Atherosclerosis Study. Endarterectomy for asymptomatic carotid artery stenosis. *JAMA* 1995; 273:1421–1428.

3. European Carotid Surgery Trialists' Collaborative Group. MRC European Carotid Surgery Trial: interim results for symptomatic patients with severe (70–99%) or with mild (0–29%) carotid stenosis. *Lancet* 1991; 337:1235–1243.

4. Barnett HJM, Taylor DW, Eliasziw M, et al. Benefit of carotid endarterectomy in patients with symptomatic moderate or severe stenosis. *N Engl J Med* 1998; 339:1415–1425.

5. Byrd S, Robless P, Baxter A, Emson M, Halliday A. Carotid duplex ultrasonography: importance of standardisation. *Int Angiol* 1998; 17:248–254.

6. Huston J III, James EM, Brown RD Jr, et al. Redefined duplex ultrasonographic criteria for diagnosis of carotid artery stenosis. *Mayo Clin Proc* 2000; 75:1133–1140.

7. Grant EG, Duerinckx AJ, El Saden S, et al. Doppler sonographic parameters for detection of carotid stenosis: is there an optimum method for their selection? *AJR Am J Roentgenol* 1999; 172:1123–1129.

8. AbuRahma AF, Robinson PA, Strickler DL, Alberts S, Young L. Proposed new duplex classification for threshold stenoses used in various symptomatic and asymptomatic carotid endarterectomy trials. *Ann Vasc Surg* 1998; 12:349–358.

9. Carpenter JP, Lexa FJ, Davis JT. Determination of duplex Doppler ultrasound criteria appropriate to the North American Symptomatic Carotid Endarterectomy Trial. *Stroke* 1996; 27:695–699.

10. Hood DB, Mattos MA, Mansour A, et al. Prospective evaluation of new duplex criteria to identify 70% internal carotid artery stenosis. *J Vasc Surg* 1996; 23:254–261.

11. Carpenter JP, Lexa FJ, Davis JT. Determination of sixty percent or greater carotid artery stenosis by duplex Doppler ultrasonography. *J Vasc Surg* 1995; 22:697–703.

12. Brownman MW, Cooperberg PL, Harrison PB, Marsh JI, Mallek N. Duplex ultrasonography criteria for internal carotid stenosis of more than 70% diameter: angiographic correlation and receiver operating characteristic curve analysis. *Can Assoc Radiol J* 1995; 46:291–295.

13. Moneta GL, Edwards JM, Papanicolaou G, et al. Screening for asymptomatic internal carotid artery stenosis: duplex criteria for discriminating 60% to 99% stenosis. *J Vasc Surg* 1995; 21:989–994.

14. Neale ML, Chambers JL, Kelly AT, et al. Reappraisal of duplex criteria to assess significant carotid stenosis with special reference to reports from the North American Symptomatic Carotid Endarterectomy Trial and the European Carotid Surgery Trial. *J Vasc Surg* 1994; 20:642–649.

15. Moneta GL, Edwards JM, Chitwood RW, et al. Correlation of North American Symptomatic Carotid Endarterectomy Trial (NASCET) angiographic definition of 70% to 99% internal carotid artery ste-

- nosis with duplex scanning. *J Vasc Surg* 1993; 17:152-159.
16. Umemura A, Yamada K. B-mode flow imaging of the carotid artery. *Stroke* 2001; 32:2055-2057.
 17. Perkins JM, Galland RB, Simmons MJ, Magee TR. Carotid duplex imaging: variation and validation. *Br J Surg* 2000; 87:320-322.
 18. Grant EG, Duerinckx AJ, El Saden SM, et al. Ability to use duplex US to quantify internal carotid arterial stenoses: fact or fiction? *Radiology* 2000; 214:247-252.
 19. Beebe HG, Salles-Cunha SX, Scissons RP, et al. Carotid arterial ultrasound scan imaging: A direct approach to stenosis measurement. *J Vasc Surg* 1999; 29:838-844.
 20. Soulez G, Therasse E, Robillard P, et al. The value of internal carotid systolic velocity ratio for assessing carotid artery stenosis with Doppler sonography. *AJR Am J Roentgenol* 1999; 172:207-212.
 21. Ranke C, Creutzig A, Becker H, Trappe HJ. Standardization of carotid ultrasound: a hemodynamic method to normalize for interindividual and interequipment variability. *Stroke* 1999; 30:402-406.
 22. Derdeyn CP, Powers WJ. Cost-effectiveness of screening for asymptomatic carotid artery disease. *Stroke* 1996; 27:1944-1950.
 23. Griewig B, Morgenstern C, Driesner F, Kallwellis G, Walker ML, Kessler C. Cerebrovascular disease assessed by color-flow and power Doppler ultrasonography: comparison with digital subtraction angiography in internal carotid artery stenosis. *Stroke* 1996; 27:95-100.
 24. Srinivasan J, Mayberg MR, Weiss DG, Eskridge J. Duplex accuracy compared with angiography in the Veterans Affairs Cooperative Studies Trial for Symptomatic Carotid Stenosis. *Neurosurgery* 1995; 36:648-653.
 25. Hunink MG, Polak JF, Barlan MM, O'Leary DH. Detection and quantification of carotid artery stenosis: efficacy of various Doppler velocity parameters. *AJR Am J Roentgenol* 1993; 160:619-625.
 26. Bluth EI, Stavros AT, Marich KW, Aufrechtig D, Baker JD. Carotid duplex sonography: a multicenter recommendation for standardized imaging and Doppler criteria. *RadioGraphics* 1988; 8:487-506.
 27. Brown PB, Zwiebel WJ, Call GK. Degree of cervical carotid artery stenosis and hemispheric stroke: duplex US findings. *Radiology* 1989; 170:541-543.
 28. Carroll BA. Duplex sonography in patients with hemispheric symptoms. *J Ultrasound Med* 1989; 8:535-540.
 29. de Virgilio C, Toosie K, Arnell T, et al. Asymptomatic carotid artery stenosis screening in patients with lower extremity atherosclerosis: a prospective study. *Ann Vasc Surg* 1997; 11:374-377.
 30. Alexandrov AV, Brodie DS, McLean A, Hamilton P, Murphy J, Burns PN. Correlation of peak systolic velocity and angiographic measurement of carotid stenosis revisited. *Stroke* 1997; 28:339-342.
 31. Fillinger MF, Baker RJ Jr, Zwolak RM, et al. Carotid duplex criteria for a 60% or greater angiographic stenosis: variation according to equipment. *J Vasc Surg* 1996; 24:856-864.
 32. Howard G, Baker WH, Chambless LE, Howard VJ, Jones AM, Toole JF. An approach for the use of Doppler ultrasound as a screening tool for hemodynamically significant stenosis (despite heterogeneity of Doppler performance): a multicenter experience—Asymptomatic Carotid Atherosclerosis Study Investigators. *Stroke* 1996; 27:1951-1957.
 33. Kuntz KM, Polak JF, Whittemore AD, Skillman JJ, Kent KC. Duplex ultrasound criteria for the identification of carotid stenosis should be laboratory specific. *Stroke* 1997; 28:597-602.
 34. Zwiebel WJ, Austin CW, Sackett JF, Strother CM. Correlation of high-resolution, B-mode, and continuous-wave Doppler sonography with arteriography in the diagnosis of carotid stenosis. *Radiology* 1983; 149:523-532.
 35. El-Saden SM, Grant EG, Hathout GM, Zimmerman PT, Cohen SN, Baker JD. Imaging of the internal carotid artery: the dilemma of total versus near total occlusion. *Radiology* 2001; 221:301-308.
 36. Pan XM, Saloner D, Reilly LM, et al. Assessment of carotid artery stenosis by ultrasonography, conventional angiography, and magnetic resonance angiography: correlation with ex vivo measurement of plaque stenosis. *J Vasc Surg* 1995; 21:82-88.
 37. Johnston DC, Eastwood JD, Nguyen T, Goldstein LB. Contrast-enhanced magnetic resonance angiography of carotid arteries: utility in routine clinical practice. *Stroke* 2002; 33:2834-2838.
 38. Ozaki CK, Irwin PB, Flynn TC, Huber TS, Seeger JM. Surgical decision making for carotid endarterectomy and contemporary magnetic resonance angiography. *Am J Surg* 1999; 178:182-184.
 39. Marcus CD, Ladam-Marcus VJ, Bigot JL, Clement C, Baehrel B, Menanteau BP. Carotid arterial stenosis: evaluation at CT angiography with the volume-rendering technique. *Radiology* 1999; 211:775-780.
 40. Fox AJ. How to measure carotid stenosis. *Radiology* 1993; 186:316-318.